Rosenow EC (1919) Studies on elective localization.
J Dent Res 1: 205 - 249.

STUDIES ON ELECTIVE LOCALIZATION

Focal Infection with Special Reference to Oral Sepsis[1]

E. C. ROSENOW

The Mayo Foundation, Rochester, Minnesota

CONTENTS

INTRODUCTION

That foci of infection, often insignificant and symptomless in themselves, are a cause of systemic disease is indicated by many facts. Clinical studies have shown that focal infections are present in demonstrable form in a high percentage of the sick, including children. Thorough removal of foci of infection is followed by improvement in the general health and frequently by improvement or cure of distant local and systemic diseases, provided the changes are not too far advanced. Indeed, improvement has occurred so often that many physicians have come to regard these observations as proof of etiologic relationship and, if improvement does not follow the removal of

[1] Presented to the First District Dental Society of the State of New York, at a meeting in New York City, March 3, 1919. See page lxxii, of the section on Proceedings of Dental and Stomatological Societies, for a report of the discussion of this paper at that meeting.

a given focus, it is considered presumptive evidence either that the particular operation was not properly performed or that other foci exist. Exacerbation of systemic conditions immediately following the removal of certain foci of infection further suggests causal relationship. The idea of an etiologic relationship is not new, and relief of systemic conditions following the removal of foci of infection is mentioned in the older medical literature.

Rush in 1801, cited by Duke (10), after mentioning a number of striking cures which followed extraction of diseased teeth, made the following statement: "I have been made happy by discovering that I have only added to the observations of other physicians, in pointing out a connection between the extraction of decayed and diseased teeth and the cure of general diseases." Miller (28) in 1889 demonstrated that infection of the mouth may cause constitutional disease. Pyorrhea is mentioned as a causative factor in pathologic conditions of the joints, and tonsilitis as frequently accompanying rheumatic fever. Black (4) emphasizes the importance of dental lesions in ocular disease and, in a review of the older medical literature, gives numerous instances indicating causal relationship between dental lesions, particularly in the form of alveolar abscess at the root apex and pus pockets along the side of the root, to diseases of the eye. The relationship between ill health and infections of the mouth was thought in earlier years to be due chiefly to the swallowing of pus and of putrid material.

Notwithstanding the repeated suggestions of etiologic relationship, the medical and dental professions, as a whole, remained indifferent until Billings (2, 3) and his co-workers made their extensive clinical observations and correlated experimental studies in animals (7, 33) demonstrating the importance of septic foci, even when small, as sources of chronic infections conveyed by the blood stream. The broader conception of this interrelationship, well expressed by the term "focal infection," may therefore be regarded as having had its origin in recent years. The experimental studies included dental foci as well as localized infections in other parts of the body. As early as 1908 (33) endocarditis was produced by intravenous injection of the respective strains from a case each of staphylococcus and streptococcus viridans endocarditis, which cases were clearly the

result of dental infections. The combined clinical and experimental studies of Hartzell (16, 17), Hartzell and Henrici (18), Gilmer (12), Gilmer and Moody (13), and Moody (29), emphasized the importance of dental foci as sources of systemic infections. For a detailed consideration of results of numerous clinical and roentgenologic studies, and an exhaustive bibliography, Duke's excellent monograph (10) on this subject should be consulted.

Experimental studies have shown that foci of infection in a given case may harbor the same type of bacteria that is found in distant lesions; that intravenous injection of the freshly isolated strains both from the focus and from the diseased organs is followed by localization and lesions in organs corresponding to those involved in the patient from whom the bacteria were isolated; and that, from the lesions produced experimentally, the organism may be isolated in pure culture, the disease again reproduced, and the organism again isolated. Moreover, immunologic evidence indicating an intimate relationship is not lacking. The bacteria having elective localizing power may be agglutinated specifically by the serum of the patient (5). In my own studies, the elective localizing power of the freshly isolated streptococci found in the focus or in systemic lesions has been demonstrated in appendicitis, ulcer of the stomach, cholecystitis, rheumatic fever (36), erythema nodosum (39), herpes zoster, myositis, chronic septic endocarditis (34), epidemic parotitis, and acute anterior poliomyelitis (40, 45). A fuller discussion of these studies may be found in the writer's original papers published in the *Journal of Infectious Diseases* and the *Journal of the American Medical Association* during the past four years.

The results in ulcer have been verified in the main and extended by Helmholz (19) and by Hardt (15), and those in cholecystitis by Brown (5). The elective localizing power of streptococci and colon bacilli from urinary infections has been demonstrated by Helmholz and Beeler (20). A number of workers, on the other hand, have failed to obtain evidence of the elective localizing power of streptococci or other bacteria isolated from foci of infection, and even of strains from the infected tissues.

In my own experiments in this field, the primary consideration was to determine whether or not foci of infection harbor bacteria, quite

without regard to species, which may produce the disease in animals corresponding to that found in the patient. Intensive effort was made to work with the bacteria from the depth of a focus and not merely with those on the surface which might be a saprophytic flora. Pus was expressed from tonsils, the pus in pyorrhea was aspirated from the depths of the pockets by means of a glass pipette, and studies were made on selected cases. Very early in the work it was found that the bacteria concerned were often extremely sensitive to oxygen, and that the property on which elective localization depends tended to disappear promptly, especially on aerobic cultivation. The specific strain may thus be lost even in the primary culture, unless the culture medium is particularly favorable for growth, both with regard to available nutritive material and with regard to oxygen tension. The importance of oxygen tension for the cultivation of various streptococci, and the variations in this requirement for growth, have been emphasized by Gräf and Wittneben (14), by Wherry and Oliver (52), and by others.

Inability to obtain evidence of the elective localizing power of bacteria in the hands of some observers, as pointed out by Gay (11), might well be explained by insufficient attention to technical details. Henrici (18), for example, first plated his material aerobically on blood agar and then made inoculations in animals with subcultures of strains of streptococci fished from single colonies. In Moody's experiments (29) the dose was very much smaller and the animals were allowed to live for a longer time than in my experiments. As to the general disease-producing power of streptococci and other bacteria contained in dental and other foci, however, the experimental results of all workers are more in accord. Thus, Henrici produced myositis, nephritis, myocarditis, arthritis, and arteritis, with cultures from dental foci. Moody obtained similar results.

Many facts suggest that dental infections are often metastatic from foci elsewhere than in the dental area (40). The observation which I have made, that bacteria isolated from the tissues in metastatic lesions show a greater affinity for the same tissues in animals than do those isolated from the primary focus, seems to indicate that the repeated occurrence of the same type of lesion, such as pulpitis in a given case, may be the result of a blood-borne infection

from one pulp to another, as well as from infection from a focus in the tonsil. The rather common occurrence of pulpitis during or following certain epidemics of acute respiratory diseases is in harmony with this idea. That infection of the pulp may be metastatic is shown by the fact that it occurs in sound teeth, that apical abscesses are sometimes found at the roots of otherwise normal teeth whose pulp chambers have not been perforated either by treatment or decay, and that infection is occasionally found in unerupted teeth. Moreover, direct experimental evidence that this may occur has been obtained. In a previous communication, I have shown the affinity for dental pulps and dental nerves, in animals, of a streptococcus isolated from the foul pulp of a tooth of a person in whom infection of a number of pulps subsequently occurred.

I shall now outline a method for a bacteriologic and experimental study applicable to dental problems, record further data concerning the localizing power of bacteria isolated from various dental foci of infection, report detailed experiments in a few illustrative cases, and present certain deductions which may serve as useful guides in various dental procedures.

DESCRIPTION OF THE EXPERIMENTS AND THEIR RESULTS

The solution of many dental problems will depend, to a large extent, on bacteriologic studies. The usual, although standard, methods are not always sufficient. The methods should be adapted to the special conditions in this field. Streptococci and other bacteria in tissues and in chronic foci of infection, particularly those about teeth, are often extremely sensitive to oxygen. Many bacteria require partial oxygen tension and do not grow under strictly anaerobic or aerobic conditions (36). Aerobic cultivation of those less sensitive tends to destroy the property on which elective localization depends. The amount of material obtainable for inoculation and the number of bacteria in many cases of dental infection are small, and hence particularly adaptable mediums are indicated. The method of making the primary cultures should be simple so that it can readily be applied with little annoyance to the patient and operator. A method embodying the above requirements, and

similar to one I have described previously (37), has proved useful in studying the bacteriology and the localizing power of the bacteria isolated in various dental infections.

Method for the bacteriologic study of dental infections

Two mediums, dextrose-brain broth and soft dextrose-brain agar, have been found especially useful. They are prepared from meat infusion or beef extract in the usual way, and titrated so that the final product is from 0.5 to 0.7 acid to phenolphthalein. In order not to interfere with the growth of sensitive bacteria and yet to indicate their number, the agar medium is made to contain only 0.5 per cent of agar, just sufficient to jell, instead of the usual 1.5 or 2 per cent. Both of these mediums are placed in test tubes so that the column of medium is at least 8 cm. tall. Pieces of fresh brain substance, equivalent to about 1 gram, are added to the bottom of each tube to make the column approximately 10 cm. tall. The mediums are then sterilized in an autoclave at 15 pounds pressure for fifteen minutes, or in an Arnold sterilizer on three successive days. Dextrose, from a concentrated sterilized solution, is added to both mediums after sterilization to make them 0.2 per cent dextrose; also decolorized acid fuchsin (Adraid's indicator). The addition of ascites fluid, blood, or serum, just before use, while advantageous in special instances, is found unnecessary for routine work. The brain substance renders the bottom of the tube anaerobic; the top necessarily is aerobic and it follows that every gradation of oxygen pressure occurs between these two points. The growth in these liquid mediums almost invariably begins at the bottom of the tube and then forces its way upward, in some instances to the top of the medium within twenty-four hours; in others, in forty-eight or seventy-two hours, or not at all (*text-fig. 1*). Tall tubes of broth made from meat infusion in the usual way, to which 5 per cent of blood is added and 0.5 per cent of dextrose from a concentrated solution just before use, have proved specially useful in studying the localizing power of bacteria from dental foci.

The liquid mediums are specially useful for studying the localizing powers of the primary culture, but they give little indication as to the number of bacteria present in the material inoculated, and one contaminating organism from the air or elsewhere may outgrow the more parasitic organisms contained in the material under consideration. The agar medium, in conjunction with a study of smears of the material inoculated, furnishes quite accurate information as to the number of bacteria contained in the material inoculated and should be used as a control of the liquid medium.



TEXT FIG. 1. PHOTOGRAPH OF BROTH CULTURES, ILLUSTRATING THE IMPORTANCE OF THE USE OF TALL COLUMNS OF MEDIUMS IN CONNECTION WITH STUDY OF DENTAL INFECTIONS

Tube I. Dextrose-acacia broth inoculated with infected pulp of tooth in a case of iritis (Case 3458).

Tube II. Dextrose-acacia broth inoculated with the iris of rabbit showing iritis, following injection of culture from the apex of the same tooth.

Tube III. Dextrose-blood broth inoculated with the iris of the rabbit showing iritis.

The growths in tubes I and II remained limited to the lower portion of the tubes for seventy-two hours; the growth in tube III was limited to the lower portion for forty-eight hours, and then forced its way to the top during the third twenty-four hours. Aerobic blood-agar plates of tubes I and II were negative. while III showed a pure culture of Streptococcus viridans.

In the agar medium, contaminating bacteria do not outgrow those contained in the material inoculated. The bacteria live for a long time, and the properties on which elective localization depends may be retained in the deep colonies for a longer period than when grown aerobically, so that transfers to the liquid mediums for animal injections may be made at a considerable period after growth has occurred.

The material from a foul pulp or a dental canal may be inoculated directly with a broach; effort should be made to carry some of it to the deeper layers of the mediums. A granuloma, or other material from apical infections, may be emulsified in sodium chloride solution in a mortar in a specially devised sterile air chamber and then inoculated, or it may be dropped into the broth directly. Transfers from these mediums to blood agar or other mediums may be made for identification and for other studies.

In the removal of teeth some danger of contamination with the mouth flora exists even when extreme measures are adopted for sterilizing the gum margins. This danger becomes slight in proper hands and, if the agar medium yields many colonies, one may be sure that the bacteria were contained in the material inoculated. If few bacteria exist in the tissue, as may be the case in chronic granuloma, control cultures in the agar medium, of the material contained in the pulp chamber of abscessed teeth, for example, should always be made. This may be done conveniently by sterilizing the surface of the tooth in a Bunsen flame, or by dipping it in alcohol and burning the alcohol, care being taken not to overheat the tooth and thus kill the bacteria in the pulp. If cultures can not be made immediately, the tooth should be wrapped in dry sterile gauze; it should not be placed in sterile salt solution or other liquids as is so often done. The pulp chamber may be entered from the seared apical end with the aid of a flamed dental drill, or by splitting the tooth wrapped in sterile gauze in the jaws of a rigid vise. Moreover, the presence of bacteria is readily demonstrated by incubating the granuloma or other tissue in the depths of the medium for from eight to twelve hours, fixing the tissue in 10 per cent formalin, and cutting and staining sections. At the point where living bacteria occur a colony containing many bacteria is formed and, owing to the density of tissues, it is readily demonstrable microscopically. This procedure has the advantage of showing the location of the bacteria in their relation to the blood-vessels (*figs. 5, 6, 9, 10, 11, 12, 13, 16*, and *17*).

For details regarding inoculations of animals, reference should be made to the original papers on elective localization. Suffice it to state here that inoculations in animals should be made intravenously, although spe-

cific localization has been obtained in some instances following intraperitoneal inoculation. The culture to be injected should be mixed so that the bacteria grown at the different levels are included. Control cultures of the material injected should always be made, since the freshly isolated organisms tend to die quickly and a negative result may be due to this cause. At least two animals, preferably medium-sized rabbits, should be inoculated with a given culture, one with a relatively small dose (1 to 5 cc.), the other with a large dose (5 to 10 cc.). The dose in special instances may be made smaller or larger, depending on the type of bacteria at hand. If the bacteria are separated from the broth and suspended in salt solution, the dose should be increased. The animal should be anesthetized in from forty-eight to seventy-two hours after injection, and examined carefully in a bright light for lesions. Animals seemingly well have frequently shown specific lesions. Repeatedly negative results have been reported by the inexperienced investigator when unmistakable lesions were found on closer examination, especially in the case of experiments in myositis and arthritis. Cultures and sections from the lesions should, of course, be made to determine the identity of the causative organisms, especially if the primary mixed cultures are injected. The nonpathogens disappear from the circulation and the tissues with remarkable rapidity, and the specific organisms quickly localizes and produces lesions. The animal often serves as an efficient plating, separating the pathogens from the nonpathogens. This fact was emphasized some years ago when it was shown that Streptococcus viridans from endocarditis was isolated in pure culture from lesions in the heart valves, and hemolytic streptococcus was isolated from the turbid joint fluid in animals after mixtures of the two strains had been injected intravenously.

Localization of bacteria from dental foci of infection

In *table 1* is given a summary of results obtained in animals injected intravenously with cultures obtained from dental foci. The figures indicate the percentage incidence of lesions in various organs as revealed by necropsy. In cases in which lesions were not found blanks are left in the table, although in some instances lesions would no doubt have been found if sufficient time had been available to make a complete search. Owing to the frequency with which colon bacilli contaminate primary cultures from pyorrhea pockets, some of the cultures injected had been plated on blood agar. On analysis,

this was found to be the reason for the relatively low total incidence of elective localization in some of the diseases studied. In instances in which the primary cultures were injected, the tendency to localize electively was usually well marked. Only one culture was made in each case. It was not intended to obtain a culture from the focus at any particular time, as during an exacerbation of symptoms, although cultures happened to be obtained during such periods in some instances. The table records the results obtained from injecting 151 animals with cultures from 42 cases.

The incidence of lesions in the organs or tissues in the animals, corresponding to those involved in the patient, was relatively high in myositis and dental neuritis, ulcer of the stomach, appendicitis, neuritis, herpes zoster, multiple sclerosis, transverse myelitis, goiter, and iritis. In some cases the tendency of the streptococcus to localize electively was very striking, there being no lesions in other organs, while in other cases there were minor localizations in addition to specific localizations, indicating both a general and a specific virulence. In some the results were entirely negative. This was the case following injection of streptococci after aerobic plating on blood agar.

Localization of bacteria in pus expressed from tonsils and in emulsions of extirpated tonsils directly injected into animals

Some years ago, in studying the localizing power of the bacteria contained in tonsils in cases of rheumatic fever, "emulsions of freshly removed tonsils were found to be very toxic for rabbits, guinea-pigs, and dogs. Symptoms following injections of relatively large doses in guinea-pigs and dogs are those characteristic of anaphylaxis in each. The degree of toxicity was greatest in the emulsions from tonsils which were visibly infected and which showed the greatest numbers of bacteria in plate cultures (35)."

Dick and Burmeister (9) made a more extensive study of the toxicity of extirpated tonsils; they also found that the toxicity is in proportion to the amount of evidence of infection, particularly by hemolytic streptococci. These experiments indicate that ill effects must come from the continued absorption of toxic material from localized in-

fections aside from the actual localization and growth of living bacteria in distant organs or tissues.

Those who are inclined to minimize the importance of foci of infection as causes of systemic disease have raised the objection that in animal experiments repeated large doses of cultures are given intravenously, and that therefore localization is to be expected, but that under natural conditions this does not occur. It is a fact that elective localizations have occurred in instances in which the dose of the culture injected was very small and they have occurred even following intraperitoneal injection. But in order to simulate the conditions more closely, direct injections of bacteria that had grown in the tonsils have been made in suitable cases together with cultures made from this material.

In *table 2* is given a summary of the results of these experiments. The figures indicate the percentage incidence of localization in the various organs as revealed to the naked eye at necropsy. The blank spaces indicate the absence of lesions in these organs. Most of the animals were injected intravenously directly with a small amount of material expressed from tonsils after it had been emulsified in salt solution. The rest were injected with small doses of emulsions from tonsils. The tendency to localize electively in the organs or tissues, corresponding to those involved in the patients from whom the material was obtained, was often a striking picture. This was particularly marked in cases of chronic arthritis and myositis when a number of experiments, sufficient to be of value, were made; although even when only a few animals were injected from cases of ulcer of the stomach, nephritis, neuritis, and erythema nodosum, localization occurred in the specific organ more often than in other tissues and the lesions were more distinct. The tonsils showing the largest amount of infected material are often small and atrophic. There is little evidence of inflammatory reaction. The infection is virtually outside the tonsil in walled-off pockets and hence localization in the tonsils of animals should not be expected after the intravenous injection. Besides, the tonsils of the animals used bear little resemblance to the human tonsil.

The fact is now well known that acute exacerbations in symptoms follow the surgical removal of certain foci of infection in chronic dis-

TABLE 1*

Localization of bacteria from dental foci of infection

DISEASES	STRAINS (42)	ANIMALS INJECTED (156)	PERCENTAGE OF ANIMALS SHOWING LESIONS IN																											
			Eyes	Teeth	Skin	Lymph glands	Thyroids	Muscles	Joints	Intestines	Appendix	Stomach (hemorrhage)	Stomach (ulcer)	Duodenum (hemorrhage)	Duodenum (ulcer)	Gall-bladder	Pancreas	Spleen	Adrenals	Kidneys	Bladder	Thymus	Lungs	Pericardium	Myocardium	Endocardium	Nerves	Ganglia	Meninges	Spinal cord	Brain
Myositis and chronic arthritis	17	62	9	11	2	2	3	47	26	2		9	5			9		5	2	14		5	10	10	16	22	12			2	2
Ulcer	6	24						8	8	4		46	38	8	13	13			4				8	4							
Appendicitis	1	1									100	100																			
Neuritis	3	12						42	16	16										16	8		16	8	16	8	68	8			
Herpes zoster	4	16	13	25	19	13	6	25	31			6	6			6	6	13		13			25	6	6	6		39	19		6
Multiple sclerosis	5	12			8			25	17	8		8	8							17			8		8		8			18	33
Transverse myelitis	2	15							7	13	7	27		7		7				7							7		7	20	27
Goiter	3	9					44	11	33			11				11				11		11	11		22						
Keratitis and iritis	1	5	60	60		20	20	60	40	20	20			20								20				20	60				

* See the supplementary comment, on the data in this table on page 213.

TABLE 2*

Localization of bacteria in pus expressed from tonsils and in emulsions of extirpated tonsils after direct injection into animals

DISEASES	STRAINS (44)	ANIMALS INJECTED (71)	PERCENTAGE OF ANIMALS SHOWING LESIONS IN																							
			Tongue	Teeth	Skin	Thyroids	Muscles	Joints	Periosteum	Intestines	Appendix	Stomach (hemorrhage)	Stomach (ulcer)	Duodenum (hemorrhage)	Gall-bladder	Adrenals	Kidneys	Lungs	Pericardium	Myocardium	Endocardium	Nerves	Ganglia	Meninges	Spinal cord	Brain
Chronic arthritis and myositis	24	37		5		5	62	43	3	5		10	3				15	15		10	15			5		
Ulcer of stomach	4	5			20		40					80	80	40							20					
Cholecystitis	1	2										50	50	50	50						100					
Nephritis	2	2										50					100									
Neuritis	4	8		13			25					13										50				
Herpes zoster	3	7	14		43		29	14										14					29			
Neuralgia	1	3						33			33					66	66	33			33	100			33	
Multiple sclerosis	4	6															17	17	34						17	17
Erythema nodosum	1	1			100		100																			

* See the supplementary comment, on the data in this table, on page 215.

eases, especially those about the teeth. This is particularly likely to occur in persons with chronic disorders who appear to be hypersensitive. The danger from the removal of too many foci at one time, in these cases, was noted some years ago (1913) when a fatal exacerbation following the removal and curettement of a number of abscessed teeth occurred in a patient suffering from chronic arthritis. To quote (39):

"On February 6, 1913, tonsillectomy was followed by slight increase in temperature for a day or two. On February 16, a number of teeth were extracted, followed on the next day by fever from 102° to 105°F. for nearly three weeks, associated with pericarditis, pleurisy with effusion, bronchopneumonia, exacerbation of the joint sensitiveness, and successive crops of erythematous nodes of the skin chiefly over the forearms and legs, acute dilatation with acute multiple ulceration of the stomach shortly before death, February 28."

The sockets were curretted immediately after extraction. The importance of the gradual removal of foci, particularly in the dental area, in chronic diseases has since been emphasized especially by Hartzell (17), by Thoma (49), and by many others. The exacerbations may be due to the absorption of toxic material to which these patients are hypersensitive, to a lighting up of a more or less dormant infection in metastatic lesions, or to a localization of bacteria that gain entrance through the traumatized area from which the diseased tissue may have been only partly removed. That such localization occurs in some instances is indicated by the results obtained in the case quoted above, and by the fact that the bacteria contained in the material expressed from tonsils or contained in extirpated tonsils, in some persons who developed temporary exacerbations, showed elective localizing power in animals. Thus, a patient with simple thoracic herpes zoster developed a gangrenous herpes zoster following the expression of pus from the tonsils containing bacteria that produced herpes in animals.

Illustrative cases and experiments

Case 516. A woman, aged fifty-seven, with typical transverse infectious myelitis. Examination showed marked pyorrhea. The patient had but seven teeth remaining, and these were loose in their

sockets and surrounded by large amounts of pus. A moderate amount of pus was expressed from the tonsils.

Twenty-one animals were injected with the bacteria isolated from the pyorrheal pockets and tonsils of this patient. Fifty per cent of the animals developed lesions in the meninges and 66 per cent showed lesions in the spinal cord. Partial or complete paralysis which began in the hind extremities developed in many of the animals. Lesions in the cord consisted chiefly of hemorrhages in both the gray and white matter, and of leukocytic infiltration in the meninges and surrounding the blood-vessels. The results following the injection of cultures from the pus about the teeth were similar to those in the following experiment (rabbit 514).

Rabbit 514 was injected intravenously, October 31, 1915, with the growth from 60 cc. of ascites-dextrose broth. November 1, peculiar incoordination was noted. The animal threw itself from side to side in attempting to get on its feet, which it was not able to do on account of weakness in the hind extremities. It was extremely ataxic, and was unable to maintain its equilibrium. The respirations were increased and it responded only slightly to a pin-prick in the hind extremities. November 2, the animal was found dead. Necropsy showed marked edema and hemorrhage of the pia. A blood-clot was found between the cerebrum and cerebellum. The external surface of the dura showed marked congestion and numerous hemorrhages. The spinal fluid was turbid and hemorrhagic. There were a few small hemorrhages in the gray matter of the cerebrum and a large number in the cerebellum. Cultures of the blood, spinal fluid, brain, and cord contained short-chained streptococci and a few colon bacilli. The meninges of the cervical cord showed marked leukocytic infiltration, especially around the nerve roots, but the nerve substance was free from infiltration. The infiltrating cells were chiefly polymorphonuclear leukocytes. The medulla showed marked hyperemia of the vessels but no hemorrhagic nor leukocytic infiltration of the dura. Gram-positive diplococci were found in and adjacent to lesions, but not in tissues free from lesions.

Case 595. A middle-aged man, with typical multiple neuritis which had followed an attack of so-called influenza three months before. (The details of the history of this case are reserved for a more complete report elsewhere.) The patient's tonsils appeared quite normal on the surface but a moderate amount of pus was expressed from the poles of each. The teeth and gums were believed to be

normal, and they appeared so on the surface, but on closer examination a marked pyorrhea was found about several of the molars.

Two series of nineteen animals were injected with cultures from tonsils and teeth, and lesions of the peripheral nerves occurred in 79 per cent. The results in animals injected with cultures from the pyorrheal pockets are illustrated in the following protocols (rabbits 739, 746; guinea-pigs 156, 158).

Rabbit 739, weighing 2115 grams, was injected intravenously, March 13, 1916, with a growth from 7.5 cc. of ascites fluid. March 14, the animal was found dead. At necropsy were found marked hemorrhagic infiltration of the right musculospiral nerve, acute splenitis, and several small areas of hemorrhage in the stomach. Numerous cross sections of brain and cord showed no lesions. The localization in the musculospiral nerve is illustrated in *figure 35-A*.

Rabbit 746, weighing 1240 grams, was injected intraveuously, March 17, 1916, with 10 cc. of ascites fluid culture. March 19, the animal was found in a crouched position; it was disinclined to walk; it was lame in the left hind extremity which it held up as if it were painful. Its hair was fluffed. March 23, the symptoms were about the same. The animal was chloroformed, and at necropsy showed a large number of white lesions in the muscles, arthritis of both knees, hemorrhage, edema, and infiltration of both tibial nerves, most marked in the upper third of the left, and localized infiltration and edema adjacent to and involving the small branches of the subcutaneous nerves in various parts of the body. Blood-agar plate cultures of the blood were sterile.

Guinea-pig 156, weighing 320 grams, was injected intraperitoneally, March 17, with 5 cc. of ascites fluid culture. March 18, the animal was found dead. Necropsy showed acute peritonitis and marked hemorrhage and edema of the lower end of both posterior tibial nerves. The lesions and localizations are illustrated in *figures 31* and *35, D* and *E*.

Guinea-pig 158, weighing 330 grams, was injected intravenously, March 23, with 3 cc. of ascites-dextrose-broth culture after the strain had passed through one animal. March 24, there were no symptoms. The animal was chloroformed, and at necropsy were found swelling and hemorrhagic infiltration in a localized area in the external and internal left popliteal nerves, in the lower third of the right sciatic nerve, in the right anterior crural nerves, in two of the trunks on both sides of the sacral plexus, and in the anterior trunk of the right brachial plexus. Cultures in ascites-dextrose on blood-agar plates of the blood, kidney, muscles, and cord,

proved sterile. Cultures of the liver showed ten colonies of streptococci. Ascites-dextrose-agar shake cultures of the cord, kidney, and normal trunk of the sacral plexus remained sterile, while those of the liver showed two colonies, and those of the muscle one colony, of streptococci. The type of lesions in the nerves and the localization of the bacteria are illustrated in *figures 32* and *35-B*.

Case 621. A woman, aged fifty-three, with chronic multiple arthritis and myositis. Twenty years before, soon after a pregnancy, the patient began to have pain in the right shin just below the knee. This was temporarily relieved by hot baths, but later pain and stiffness developed in the knee, and with it pains passing from joint to joint. A vaccine prepared from Streptococcus rheumaticus was used and potassium iodid was administered, resulting in great improvement which lasted for two years. The patient then developed pain in the jaws and teeth, and the joint symptoms returned. An x-ray examination disclosed abscessed teeth, which were removed. The tonsils had been removed seven months before with some improvement. A general examination revealed multiple arthritis in all the large joints with marked destruction of joint surfaces, as shown by the x-ray, ankylosis of the knees, and almost complete fixation of both elbows. A small amount of infected lymphoid tissue in the region of the tonsil scars was found and removed. X-ray examination revealed rarefaction around the apices and roots of the first left upper molar. This tooth was extracted. Small masses of connective tissue over the apices of the roots and a partially calcified pulp were found. Improvement in the patient's condition following the removal of these foci was slight and temporary; this could be expected considering the marked changes that had already occurred.

Cultures from the granuloma of the extracted tooth in dextrose-broth yielded a large number of green-producing streptococci and a few hemolytic streptococci, while those made from the pulp contained pure cultures of green-producing streptococci. Those from the tonsils showed green-producing streptococci, Micrococcus catarrhalis, staphylococci, and small Gram-positive bacilli.

The primary cultures in dextrose-broth of each were injected into four animals. Non-suppurative arthritis, lesions in the ligaments and the

periosteum around joints and muscles, chiefly in the tendinous portion, were the predominating findings in all the animals. The two injected with the culture from the pulp also showed lesions in the pulps of teeth, while the two injected with the culture from the granuloma and tonsil, respectively, did not. (See protocols below for rabbits 813, 814, 820, 823.)

Rabbit 813, weighing 1750 grams, was injected intravenously, April 27, 1916, with 10 cc. of ascites-dextrose-broth culture from the apex of the extracted tooth. April 28, when the animal seemed quite well, it was chloroformed. Examination revealed a large hemorrhage in the periosteum on the inner aspect of the tuberosity of the left tibia, slightly turbid fluid in both knee-joints, a number of hemorrhages in the muscles and tendons about the hip-joints, a moderate number of small whitish streaks in the flat muscles about the chest and diaphragm and over the tendinous portions of the muscles of the extremities. There were two hemorrhages in the tricuspid valve, two small ones along the lesser curvature of the stomach, and a large hemorrhagic ulcer near the pylorus. There were no other lesions. Blood-agar-plate cultures from the blood and joint fluid were sterile, while cultures in ascites-dextrose-broth showed green-producing streptococci.

Rabbit 814, weighing 1210 grams, was injected intravenously, April 27, 1916, with 10 cc. of ascites-dextrose-broth culture from the pulp of the extracted left upper molar. April 28, the rabbit seemed quite well; it was chloroformed. At necropsy there were found distinctly turbid fluid in both knee-joints; a few hemorrhages in the capsule and muscles around the left knee-joint and left shoulder-joint; a few lesions in the muscles, especially in the tendinous portions about the extremities; and hyperemia and hemorrhages in pulps of teeth.

Rabbit 820, weighing 1240 grams, was injected intravenously, April 28, 1916, with the growth from 30 cc. of ascites-dextrose-broth culture from the pulp of the extracted tooth. April 29, the rabbit seemed in pain and its muscles were sore. It was chloroformed and at necropsy showed a number of hemorrhages in the periosteum near the tuberosity of the tibia, and marked hyperemia and small hemorrhages of the pulps of the teeth.

Rabbit 823, weighing 1420 grams, was injected intravenously, April 29, 1916, with 10 cc. of ascites-dextrose-broth culture from the tonsil. May 1, the rabbit seemed quite well but was distinctly muscle-sore. The animal was chloroformed. A small number of lesions were found in the muscles about the knee- and hip-joints, especially in the tendinous portions; also arthritis of the left knee, hemorrhages in the periosteum of the lateral aspect of the tibia, and hemorrhages in the periosteum under the left eye.

Case 623. G. W., middle aged physician, had repeated attacks of pain in the right gluteus maximus muscle, and occasional stiffness of the muscles of the back. The attacks varied from time to time and were much less severe after the removal of the tonsils at the end of three years, but they recurred at intervals and the patient was not quite free from stiffness and soreness in the interim. On examination at the Mayo Clinic, in April, 1916, a small abscess was found over the apex of a tooth, which was extracted. Slow but continuous improvement followed, with entire freedom from severe attacks for several years, even during ten months in the damp, cold climate of France. A small granuloma was found over the apex of the root of the extracted tooth and the canal showed a calcifying pulp.

The cultures from both showed short-chained, green-producing streptococci, a few staphylococci, a few hemolytic streptococci, and a moderate number of slightly hemolyzing streptococci.

A primary culture of the calcified pulp was injected into one rabbit, the primary culture of the granuloma into another. The results obtained from the injections are recorded in the following protocols (rabbits 818, 822).

Rabbit 818 was injected intravenously, April 28, 1916, with the growth from 30 cc. of ascites-dextrose broth from the granuloma. April 29, the animal seemed muscle-sore but otherwise well. It was chloroformed and at necropsy the fluid in knee-joints and shoulder-joints was found distinctly turbid. The right gluteus muscle was streaked with white and was hemorrhagic; and an area, almost 1 cm. in diameter, near the attachment of the muscle to the ilium, contained numerous small hemorrhages. A moderate number of lesions were scattered in the more tendinous portions of the muscles throughout the body and in the muscles about the shoulder blades. Cultures from the blood and joint fluid showed a pure culture of green-producing streptococci; those from the muscle showed a large number of slightly hemolyzing streptococci, a few green-producing streptococci, and a few Gram-negative bacilli. The microscopic appearance of the lesions in the gluteus maximus muscle, and the localization, are illustrated in *figures 28* and *33-D*.

Rabbit 822, weighing 1220 grams, was injected intravenously, April 29, 1916, with 10 cc. of ascites-dextrose-broth culture from the partially calcified pulp of the extracted tooth. At 3.00 p.m. the rabbit was found dead. Examination revealed numerous small hemorrhages, over an area 1 cm. in

diameter, in the right gluteus maximus muscle near its attachment to the ilium. A group of hemorrhages in the other muscles about the right hip-joint and a few lesions in the muscles on the right side of the chest were found. Cultures of the blood were sterile.

Case 628. A woman, aged fifty-four, had suffered from severe shooting pain in the lumbar region and back, and down the right leg to the inner side of the knee, for a period of three or four weeks fifteen months before. She had had an acute attack of cystitis eighteen months before, at which time the course of the nerve on the inner aspect of the leg was eruptive and blistered. Five months before coming to the clinic the patient had an attack, less severe, lasting three or four weeks; and, during the previous winter, weakness in the back and numbness in both thighs had been noted. X-ray examination of the lumbar spine was negative; the joints showed ankylosis. Abscesses were found at the roots of the lower right third molar and second bicuspid. The tonsils, which showed moderate infection, were removed. The teeth were extracted. The root canals were almost obliterated; neither of them was foul.

Cultures from the tonsils showed hemolytic and green-producing streptococci; and cultures from the small abscess at the apex of the molar showed a pure culture of green-producing streptococci in pairs, and in long and short chains.

Cultures from the tonsils, from the small granuloma at the apex of the molar, and from the pulp of the bicuspid, were injected into animals. The following protocols illustrate the marked tendency to localize in the lumbar nerves, and dorsal roots and ganglia (rabbits 839, 842, 845).

Rabbit 839 was injected intravenously, May 20, 1916, with 10 cc. of ascites-dextrose-broth culture from the granuloma at the apex of the molar. May 21, the animal was found dead. Necropsy showed a number of punctate hemorrhages in the nerve substance of the left external popliteal nerve and its branches to the calf of the leg. The nerve sheath was hyperemic and also showed hemorrhages. In the left sciatic nerve was one small punctate hemorrhage, in the right sciatic nerve a few hemorrhages; and one small hemorrhage was found in the right posterior tibial nerve. Very small punctate hemorrhages dotted the skeletal muscles. The external dural venous plexus was hyperemic. The spinal roots and the membranes of the cord were free from hemorrhages, except for a sharply

circumscribed subpial hemorrhage, 3 by 4 mm., surrounding the right second sacral anterior root, and one smaller hemorrhage surrounding the nerve just beyond the ganglion of the third sacral root. Numerous cross sections of the cord showed no lesions in its substance. Cultures from the blood showed pure culture of short-chained streptococci.

Rabbit 842 was injected intravenously, May 22, 1916, with 10 cc. of ascites-dextrose-broth culture from the pulp of the lower right third molar. May 23, the animal seemed well; the injection was repeated. May 25, it seemed well and was chloroformed. Necropsy revealed a few lesions of the muscles over the left hip and psoas. Distinct hemorrhagic edema surrounded the posterior roots of the fourth left cervical, and third and fourth left dorsal ganglia; and the extradural vessels in the lumbar region were markedly congested. Numerous cross sections of the brain and cord showed no lesions. Cultures of the blood in ascites-dextrose broth showed a pure growth of streptococci.

Rabbit 845 was injected intravenously, May 24, 1916, with 5 cc. of ascites-dextrose-broth culture of the streptococcus isolated from the rabbit injected with the primary culture from the tonsil. May 26, the animal moved about as if in pain; it was chloroformed. Necropsy revealed a few small hemorrhages in the bladder, a few white embolic foci in the cortex of the kidney, localized myocarditis, arthritis of both knee-joints, a few lesions in the muscles, and localized areas of hemorrhage and edema of the sheaths of the main trunks of the lumbar plexus (*fig. 21*). There was one area of hemorrhage and infiltration in the right external popliteal nerve, and also hemorrhagic edema of the external surface of the dura posteriorly and surrounding the posterior dorsal roots, chiefly in the cervical region.

Case 630. A druggist, aged forty-six, had had two attacks of epilepsy in the six weeks before his examination, and red spots had appeared on the forehead and to the right of the midline, extending back over one-half of the right side of the head. One week later, he began to suffer severe pain in the region of the right eye. A typical herpes zoster was found over the right side of the face and forehead. The tonsils were moderately infected, and x-ray examination of the teeth revealed an abscess at the roots of the lower left molar. The tonsils were removed, and the tooth was extracted.

A series of five rabbits was injected with cultures from both. Four rabbits were injected with cultures from the tonsils before and after one animal passage; all showed herpes. The result in the rabbit injected with the

culture from the granuloma at the apex of the tooth is indicated in the following protocol (rabbit 843).

Rabbit 843, weighing 1160 grams was injected intravenously, May 23, 1916, with 10 cc. of ascites-dextrose-broth culture. May 26, the animal sat around as if in pain; it was chloroformed. Necropsy showed numerous small vesicles with opaque bases on the dorsum of the tongue, chiefly on the left side. The vesicles were not ruptured and were from 0.5 to 2 mm. in diameter. The right gasserian ganglion showed a number of subcapsular hemorrhages, and a few hemorrhages were found in the valves of the heart. No lesions were found in numerous cross sections of the brain and cord. Cultures from the blood in ascites-dextrose broth showed streptococci.

Case 674. A man, aged fifty-three, had suffered from typical bilateral trigeminal neuralgia for twenty years. (The details of the history are reserved for a more complete report elsewhere.) The patient's tonsils were of moderate size, red, and contained a small amount of pus. Many of his teeth had been extracted, and the gums were retracted from those remaining. Pyorrhea was marked.

Cultures from the pus expressed from the teeth and tonsils were injected into animals. The results are illustrated in the following protocol (rabbit 908).

Rabbit 908 was injected intravenously, July 12, 1916, with the growth from 30 cc. of ascites-dextrose-broth culture from pus from around the teeth. July 14, the animal was found dead. Necropsy revealed a large hemorrhagic edematous area surrounding the right inferior dental nerve at the point of exit; a few distinct hemorrhages in the nerve sheath; a large hemorrhage and marked edema of the right superior dental nerve, extending for a distance of 1 cm. in the bony canal; multiple hemorrhages and hyperemia of the left inferior dental nerve within the submaxillary bone; and marked hyperemia, but no gross hemorrhages, in the pulp of the teeth in the left lower jaw. The injected culture contained streptococci and a Gram-negative bacillus. Blood-agar-plate culture of the blood after death showed a few streptococci and a moderate number of Gram-negative bacilli. Microscopic sections were made of the sensory root of the right gasserian ganglion, of the left inferior dental nerve, of the tooth pulp, of both superior maxillary nerves, and of the gasserian ganglia. The lesions and localizations found in these areas are shown in *figs. 29* and *34-A and B.*

Case 3368. A man, aged forty-seven, wood-worker by occupation, complained of feeling below par generally, and of recurring mild at-

tacks of rheumatic pains in the back, arms, shoulders, and through the head. The attacks tended to recur at intervals of about one month for the past three or four years. The patient also complained of a burning sensation in the mouth. A general examination was negative; systolic blood pressure, 136; diastolic pressure, 66; Wassermann test, negative. An x-ray examination of the head showed cloudy maxillary sinuses, and apical rarefaction about three teeth. The first right upper bicuspid gave no evidence of rarefaction over the apex, but was somewhat discolored, and an electric test indicated lost vitality of the nerve. The four teeth were extracted, and the bicuspid was sent for cultures by Dr. Gardner. No evidence of infection over the apex was found. The surface of the tooth was sterilized in a Bunsen flame, wrapped in sterile gauze and split open in the jaws of a vise. The pulp appeared quite normal, although it was slightly hyperemic, particularly over a small lateral area.

After the surface of a blood-agar plate had been inoculated, the pulp was placed in the bottom of a tall tube of dextrose-acacia broth, and incubated for ten hours. It was then placed in 10 per cent formalin. A pure culture of a short-chained streptococcus developed in the broth; it showed preference for anaerobic conditions, growing only in the lower two-fifths of the column of the broth (*text-fig. 1, tube I*). Microscopic examination of stained sections of the pulp showed practically no abnormalities except a small area of round cell infiltration along one margin (*fig. 12*). Sections of the pulp, after incubation in the broth for ten hours, showed a number of capillaries plugged with streptococci (*fig. 12*), together with large numbers of bacteria in the area of infiltration (*fig. 13*).

The primary broth culture was injected intravenously into two rabbits. The one developed marked double iritis, hemorrhage and infiltration in the pulps of teeth, and a number of hemorrhages in the muscles. The rabbit which received a smaller dose showed symptoms of iritis, injection of vessels, photophobia, and lacrimation for a number of days, and then recovered. The animal was anesthetized on the third day. Slightly turbid fluid in the knee joints was found, but no other lesions.

Cultures from the iris of the rabbit that showed marked iritis (*text-fig. 1, tube III*) were injected into two rabbits. Both of these developed temporary symptoms of iritis. One had outspoken lesions of the pulps of the

teeth, and both had lesions in muscles and joints. One also had hemorrhage in the stomach and heart valves. The following experiments illustrate the results obtained with the culture from the focus in this case (rabbit 1720).

Rabbit 1720, weighing 1610 grams, was injected, April 15, 1919, with 7 cc. of a forty-eight hour dextrose-acacia-broth culture from the pulp of the right upper first bicuspid. April 16, the left eyelids were glued together by exudate. The vessels of the iris and of the sclera surrounding the cornea were markedly congested, but there was no turbidity of the anterior chamber. The right eye was normal. The rabbit appeared muscle-sore, generally weak, and its respirations were slightly increased. April 17, there was marked injection of the vessels of the iris and sclera surrounding the cornea in both eyes. The right eye was enucleated by Dr. Benedict. Examination showed hemorrhagic exudate in the posterior surface and peripheral margins of the iris. The rabbit appeared to be weak and muscle-sore, and tended constantly to crouch and to lie on its side as if it were painful to stand. April 18, the animal was extremely weak, and just able to walk. The fluid in the anterior chamber of the left eye was very turbid. The rabbit died at 10.30 a.m. Examination showed a moderate number of hemorrhagic lesions of the muscles, especially surrounding the nerve trunks of the abdominal wall; also small hemorrhages of the tendinous portion of the muscles of the extremities and deep muscles of the shoulder and hip joints. The peridental membrane on the left lower incisor, especially near the apex, and the pulp of the tooth, were hemorrhagic and edematous, and microscopically the pulp showed leukocytic infiltration and diplococci adjacent to or in hemorrhagic areas (*fig. 15*). In the corresponding left inferior dental nerve was a number of small punctate hemorrhages. The pulp of a number of the molars was hemorrhagic. A few small circumscribed hemorrhages were found in the cecum. The uterus contained three necrotic placental masses; the peritoneum over these areas was hyperemic and covered with a thin layer of fibrin. The lungs, stomach, heart, kidneys, adrenals, superior dental nerves, joints, brain, and cord were free from lesions. Blood-agar plates and tall-tube cultures, in dextrose-broth of the vitreous and turbid fluid in the anterior chamber of the extirpated eye, were negative. Blood-agar-plate cultures of the turbid fluid of the anterior chamber of the left eye after death showed a moderate number of green colonies of streptococci and a few colonies of colon bacilli. Dextrose-acacia-broth cultures of this fluid contained many colonies in the fibrinous film in the middle portion of a tall tube, but no diffuse growth. A diffuse cloud in the lower 2 cm., but no growth in the rest of the tube, developed in the dextrose-acacia-broth cultures from

the iris of the extirpated right eye (*text-fig. 1, tube II*). Cultures from the iris of the left eye, after death, in dextrose-blood broth, showed a marked diffuse cloud in the lower half of the tube, and a less dense cloud in the upper half, due to the short-chained streptococci in pure culture. A few colonies of green-producing streptococci developed in blood-agar-plate cultures from the fresh hemorrhagic pulp of the left lower incisor, while those from corresponding normal pulp of the right upper incisor were sterile. A moderate number of green-producing streptococci and a few colon bacilli were found in cultures from the blood.

Case 3458. A woman, aged twenty-three, came to the Clinic because of pain in the left eye. Three days before, a foreign body had become lodged in the eye, causing considerable pain and lacrimation. The eye was washed with boric acid solution, and the patient felt relieved, though the pain prevented her from sleeping during the night. The following day, while she was working, the eye gradually became more painful. Dr. Benedict found injection of the conjunctiva, a clear cornea, a normal fundus, but no evidence of a foreign body. The patient subsequently developed a typical attack of keratitis and iritis. A general examination was negative. The dental examination by Dr. Gardner showed four impacted molars, and a fracture of the roots of both upper central incisors, sustained eleven years previously. The impacted and fractured teeth were extracted, and the sockets of the incisors curetted. The patient made a rapid recovery. The pulp of the right upper central incisor was calcified; the pulp chamber of the left upper central incisor was enlarged and filled with foul smelling pus, and this tooth had a small granuloma over its apex.

Gram-positive diplococci were identified in smears from the pus; also a large number of fusiform bacilli, and cocci of varying sizes. A blood-agar plate of this pus produced a moderate number of indifferent colonies of staphylococci, but no green nor hemolytic streptococci. Cultures in dextrose-blood broth of the foul pulp produced a diffuse cloud, due to short-chained streptococci. A blood-agar plate of this culture showed green-producing streptococci in pure form. Cultures in dextrose-blood broth of the granuloma over this tooth, of a splinter of bone from between the two teeth, and of the calcified pulp of the right incisor, showed in twenty-four hours a diffuse cloud in the

lower two-thirds of the tube, gradually rising to the top. The same type of streptococcus was isolated from blood-agar plates of the dextrose-blood-broth culture as from the foul pulp. Microscopic sections of the granuloma showed chiefly old dense fibrous tissue containing various sized, highly cellular areas (*fig. 7*). The areas of infiltration contained fibroblasts, plasma cells, endothelial cells, arranged in rows resembling capillaries, and a moderate number of leukocytes. Gram stain of the fresh granuloma showed an occasional diplococcus, usually in or adjacent to the cellular areas or blood vessels. At the apex of the granuloma near a blood vessel was found an area (*fig. 7*) which contained a considerable number of diplococci (*fig. 8*).

Primary dextrose-blood-broth cultures of the foul pulp, of the calcified pulp, and of the granuloma, were injected intravenously into three rabbits, respectively. All of these had iritis and lesions of nerve trunks, and one had lesions of the muscles. The first two rabbits (1699, 1700) had marked lesions of the pulps and contiguous structures of teeth, the third did not. The culture of streptococcus from the iris of one of the rabbits (1699) was injected into two others. Both developed lesions of the muscles, and lesions around the pulps of teeth and dental nerves and in the jaws. Only one of the five rabbits died from injections; the others were anesthetized for examination in from three to six days.

Rabbit 1699, albino, weighing 1100 grams, was injected intravenously, April 30, 9.00 a.m., with 3.5 cc. of the dextrose-blood-broth culture of the foul pulp. A small amount of sterile sand was added to a few drops of this culture and placed in the right conjunctival sac. At 8.00 p.m., the vessels of the iris and surrounding conjunctiva were congested, and both eyes were affected by lacrimation and photophobia. The rabbit seemed well otherwise. May 1, 7.00 a.m., the congestion of the vessels of the eyes was more marked (*fig. 2*), and the animal appeared muscle-sore, inactive, with a tendency to crouch on its abdomen. The fluid in the anterior chambers was cloudy. At noon, the animal appeared weaker; congestion in the eyes had diminished. At 8.00 p.m., the animal jumped out of its basket in a convulsive seizure and died in violent convulsion fifteen minutes later. The circumcorneal congestion disappeared as death occurred.

The examination was made immediately. The iris of each eye was opaque and showed focal hemorrhages. The fluid in the anterior chamber was turbid. There were numerous hemorrhages of the posterior aspect of the

iris and in the ciliary body (*fig. 3*). The base of the appendix and the mesenteric lymph glands draining the appendix were swollen and hemorrhagic. There was marked degeneration of the myocardium, hemorrhages of the superficial muscles and aponeurosis about the thorax (*fig. 23*), punctate hemorrhages in the thymus, numerous subendothelial hemorrhages in the septal wall, in the left ventricle, and in the papillary muscles. The parathyroid glands were extremely red and appeared edematous and swollen. The thyroid was hyperemic. In the first centimeter of the duodenum were a few small punctate hemorrhages; the mucous membrane of the cardiac end of the stomach was hyperemic; the lymph glands beneath the angle of the jaw and ear, and along both superior maxillary nerves, were edematous and hemorrhagic; the axillary and inguinal lymph glands were normal; those in the popliteal spaces were hemorrhagic and edematous, and the posterior tibial nerves were swollen and hemorrhagic. The periosteum (*fig. 23*) opposite the right lower incisor was edematous and easily separated from the bone; the tooth was loose in the socket; the peridental membrane and the pulp were edematous and hemorrhagic. The corresponding inferior dental nerve was hemorrhagic and a number of the pulps of the molars on that side were hemorrhagic and edematous (*fig. 23*). The pulp of the left lower incisor, and the left inferior dental nerve, were normal. The superior dental nerves were edematous and contained a few punctate hemorrhages. Smears from the hemorrhagic area in the periosteum and from three dental pulps showed a Gram-positive diplococcus, but no other bacteria. Blood-agar-plate cultures of the blood, of the fluid from the anterior chamber, and of the pulp of the right lower incisor, were negative. Dextrose-blood-broth cultures of the tissue of the iris, and the pulp of the right lower incisor, showed diffuse growth of a short-chained streptococcus, beginning at the bottom of the tube and gradually forcing its way to the top. Sections of the eyes showed marked hemorrhage and leukocytic infiltration of the ciliary body and iris (*fig. 19*). Gram stains showed scattered diplococci in and adjacent to areas of hemorrhage (*fig. 20-B*).

Rabbit 1700, a female weighing 1720 grams, was injected intravenously, April 30, with 5 cc. of the dextrose-blood-broth culture from the calcified pulp of the right upper central incisor. A few drops of culture were mixed with sterile sand and dropped into the right conjunctival sac. May 1, the animal appeared fairly well, but there was lacrimation and moderate congestion of the vessels of both eyes. May 2, the eyes appeared normal, and the rabbit seemed well generally. The animal did not use the right hind leg, which it held up as if it were painful. Slight pressure along the sciatic

nerve and posterior aspect of the legs seemed to cause pain. The joints were not swollen. May 3, conditions were about the same, and chloroform was administered slowly; the animal went to sleep without a struggle.

Marked infiltration and edema of the subcutaneous tissue of the posterior and lateral aspects of the lower two-thirds of the right leg and plantar surface of the foot were found. There was hemorrhage and infiltration along the sheaths of the nerve trunks and sheaths of the plantar surface of the right foot. This infiltration was most marked immediately surrounding the lower one-third of the posterior tibial and accompanying nerve in the right leg. The tissues surrounding these nerves were extremely edematous and swollen, including the tendon Achilles and its bursa on the posterior aspect of the os calcis (*fig. 22*). The plantar infiltration and suppuration followed the nerve trunk and extended into the tissues and sheaths of the tendons. The ankle and phalangeal joints were normal. The left posterior tibial nerve showed a few hemorrhages in the upper one-third, and the bursa of the attachment of the tendon Achilles was only slightly swollen. A number of small hemorrhages was associated with whitish streaks and localized edema in the more tendinous portion of the muscles of the anterior aspect of the left tibia, with a large area surrounding a small nerve in the deeper layer of the muscles. There was an area of hemorrhage and infiltration in the intercostal muscles beneath the shoulder blade of the right thorax (*fig. 26*), and a large hemorrhage associated with edema in the periosteum of the upper left jaw opposite the apex of the upper left incisor (*fig. 25*). The left superior dental nerve was hemorrhagic and edematous, with a number of whitish areas of infiltration. The pulp of the left upper incisor was hyperemic and edematous. The pulps of the molars on the left side were edematous; those on the right side appeared normal. The right superior dental pulp and nerve were normal. There were no lesions of the nerve trunks other than those mentioned.

The uterus was much enlarged and contained five almost-full-term fetuses. In the *first fetus* were a few whitish lesions of the muscles of the abdominal wall along the blood vessels and nerve trunks; a few hemorrhages in the muscles about the neck and between the toes in the subcutaneous tissues of the plantar surface of the left foot; hemorrhage and edema in the posterior aspect of the left leg; and around the ankle-joint of the right leg was a group of hemorrhages. In the *second fetus* was a group of hemorrhages between the third and fourth toes and in the upper aspect of the little toe, and a group of hemorrhages in the muscles of the anterior aspect of the left ear. In the *third fetus* was a number of hemorrhages of the muscles of the inner and upper aspects of the left tibia. In the *fourth fetus* the only

lesions were small punctate hemorrhages of the intercostal muscles and muscles of the back (*fig. 27*). In the *fifth fetus* were small hemorrhages in the skin over the left shoulder blade.

Cultures from the heart blood and amniotic fluid of the adult rabbit were negative. Cultures from the pus around the right posterior tibial nerve of the adult rabbit showed countless numbers of colonies of green-producing streptococci. In the smears were moderate numbers of diplococci. No growths were produced from cultures of the fluid in the eyes and brain substance of two of the fetuses, while dextrose-blood broth inoculated with the hemorrhagic muscles of the left leg of the third fetus showed, in twenty-four hours, diffuse growth of short-chained streptococci in the lower portion of the tube, that rose to the top in seventy-two hours. In the blood-agar plate of this culture was the type of green-producing streptococcus injected into the adult rabbit in pure form.

SUMMARY AND DISCUSSION

Experimental findings

By the use of the method described it is possible to obtain fairly accurate information of the number and kind of mircoörganisms in various dental infections, as well as their location in relation to the blood supply. The cultures from apical abscesses and pulps of teeth, in my hands as in the studies of Henrici and Hartzell (18), Moody (29), and others, showed the green-producing streptococcus, often in predominating numbers, as an almost constant organism in these areas. A detailed study of some of the isolated strains is reserved for a more extensive study of streptococci from various sources. Streptococci were often isolated in pure culture, in some instances even though smears from the foul-smelling pus also showed staphylococci and fusiform bacilli. All the cultures of streptococci manifesting a preference for anaerobic conditions in the primary culture, as illustrated in *text-figure 1*, ultimately became aerobic when, with few exceptions, they resembled Streptococcus viridans. In no instance did they remain strictly anaerobic. Slightly hemolyzing and indifferent streptococci and indifferent staphylococci occurred next in frequency. The fusiform bacillus was found almost constantly in pulp chambers or abscesses containing foul-smelling pus, but never in pure

culture. Colon bacilli were commonly found, together with streptococci, staphylococci, fusiform bacilli, and spirochetes, in pyorrhea pockets, but they were only rarely isolated from apical infections.

The percentages indicating the localizations in the experiments summarized in *tables 1* and *2* do not adequately represent the results obtained. In the former, injections were frequently made after plating the organisms, and, in both, lesions in organs, other than those affected in the patient harboring the focus, were usually less marked or trivial. The experiments in animals, recorded in detail, revealed the striking tendency of the bacteria to localize in the tissues involved in each of the following diseases: transverse myelitis, multiple neuritis, chronic arthritis and myositis, gluteus myositis, lumbar neuritis, herpes zoster, trigeminal neuralgia, mild myositis, keratitis, and iritis.

The results following injection of bacteria contained in small amounts of pus from tonsils show that the bacteria grown in the focus may have elective localizing power, and that small numbers of these are sufficient to cause lesions in animals corresponding to those in the patient. The experiments with emulsions of tonsils show that the degree of toxicity was proportional to the amount of infection in these organs (35). On the basis of these experiments, the harm from foci of infection must be considered as being due to the absorption of toxic bacterial products, as well as to the entrance of the living bacteria into the circulation and their localization. The number of bacteria in acute lesions is sometimes so small as to be difficult to find and as to suggest that the specific lesions are due in part to the formation of toxic products. This possibility is also suggested by the observation that specific localizations occur with smaller doses of the broth culture directly injected than with the centrifuged bacteria resuspended in salt solution. The focus moreover may supply alien proteins, toxic or otherwise (37), to which an individual as a whole, or the involved tissues such as joint structures, may have become highly sensitive. Clinical and experimental evidence (26) of the possible occurrence of harm by this mechanism is not lacking.

The localizations following injection of the cultures from the case of mild myositis (rabbit 3368) and from the case of acute iritis (rabbit 3458) are in accord with the results obtained by Irons, Brown and

Nadler (24) in their study on experimental iridocyclitis in rabbits and with the results I have reported previously. These results show that experimental iritis and myositis or arthritis are prone to occur simultaneously (38). This was found to be the case following injection of strains isolated from rheumatic myositis and allied conditions, as well as of laboratory strains of streptococci when they had attained a certain grade of virulency from animal passage (38). Moreover, the results in animals are in harmony with those in persons who have had repeated attacks of iritis and who are prone to have myositis and similar conditions. The occurrence of lesions in the fetuses similar to those that occurred in the mother rabbit (1700) is especially interesting. The amniotic fluid was sterile. No bacteria were found in normal tissues in the fetuses, while the tissues with lesions contained the streptococcus injected, and hence may be regarded as the result of embolic infection. This is a special indication of elective localization, since the bacteria must have passed through the walls of four sets of capillaries before they could lodge in the specific tissue. Specific localizations in the fetuses have been noted also in experiments in influenza. In this connection it should be mentioned that Curtis (6) found that streptococci, associated with spontaneous abortion in women, when injected intravenously into pregnant rabbits, tend to lodge in the uterus and to produce abortion or absorption of fetuses. The view held by many obstetricians (48), that foci of infection predispose to eclampsia, abortions, and to ill health of the fetus, would thus seem to have experimental basis.

The inability to obtain the specific localization at any one time in animals injected with bacteria from these foci should not necessarily be considered as evidence that a causal relationship might not have been present at some other time, for I have shown repeatedly that peculiar infecting powers may be lost in a focus just as in artificial media and from animal passage, a finding which Irons, Brown, and Nadler corroborate (24). The occurrence of lesions other than the specific ones in organs or tissues of animals injected with relatively large doses should not detract materially from the general truth of the elective localization theory, and should be looked on as evidence for, rather than against, causal relationship between focus and systemic disease. The non-specific lesions are usually relatively slight, roughly

in proportion to the size of the dose, and may not occur if the dose is accurately gauged. They tend to occur in the same type of tissues in a series of animals. The tissues involved commonly correspond to those frequently affected in persons with certain diseases which are not demonstrably present at a given time, but which may become manifest later.

In a previous paper it has been shown that cultures from chronic foci of infection at the time of acute attacks of systemic disease, such as appendicitis, tend to reproduce the acute disease in animals, but that this may not be the case subsequently. This finding has been interpreted by some observers (22) to mean that the organism in appendicitis enters the appendix from its lumen, passes into the blood stream, and on to the focus. This is conceivably possible in acute appendicitis but in other diseases, which must be regarded as of embolic origin, this interpretation would seem illogical. Experimental appendicitis follows intravenous injection of the proper strains, a fact which has been noted also by Helmholz and Beeler (20), but it has never been produced by placing the bacteria into the uninjured lumen of the appendix of animals. An acute exacerbation in the focus should occur if the bacteria from acute infections suddenly become lodged in the chronic focus, but such exacerbations do not occur. It is a well-established clinical observation that systemic invasion commonly occurs not at the time of an acute attack of tonsilitis or of acute pulpitis, but some time after the acute symptoms have subsided, usually in from ten days to a month. It is during this time, as I have pointed out, that bacteria may acquire specific infecting power. The changes in the focus take place gradually and hence are not accompanied by evidence of acute exacerbation. Accordingly, the interpretation that the systemic disease is the result of embolic infection, whether aided or not by local predisposing factors, from a distant focus, would seem more true to fact.

Howe (22) questions the significance of my experiments on the production of ulcer by intravenous injection of streptococci. He states:

"Bertram says that for half a century it has been recognized that a peptic ulcer forms when a circumscribed area of the stomach loses its normal resistance through malnutrition or neurosis to the digestive effect of

the gastric juice, and is digested. Burge and Burge assert that decreased resistance of a circumscribed area of the stomach to gastric juice due to a decreased oxidative process of the cells of the area, followed by subsequent digestion of the area by pepsin, is the explanation of gastric ulcer."

These observations still leave the cause of the local disturbance undetermined. The results of my experiments indicate that the local malnutrition or neurosis described by Bertram, and the circumscribed area of decreased oxidation described by Burge and Burge, commonly are due to embolic localization of streptococci having affinity for the mucous membrane of the stomach.

The tendency to systemic invasion in acute infections about the teeth and jaws is recognized by all. Some observers have suggested that the rôle played in the causation of systemic ills by chronic localized infections about the teeth and jaws, particularly infected pulps, apical abscesses, and granulomas, must be unimportant because nature's efforts are quite sufficient to protect the individual who harbors them; that the wall of connective tissue in a granuloma makes invasion of the blood stream by bacteria impossible or highly improbable; and that, since these conditions are so often free from symptoms, they must be harmless. In the light of the results of the experiments reported in this paper, this explanation does not seem tenable. It is a well-known fact that new blood vessels are formed constantly during inflammatory reactions following injury of tissue from any cause. It has been shown that the bacteria in granulomas and pulps of teeth occur chiefly where the connective tissue is highly cellular or embryonic in character, where leukocytic and round cell infiltration is present, where new blood vessels are being formed, and adjacent to or within the larger blood vessels (*figs. 5* to *13*). It is evident, therefore, that the bacteria do not need to pass through a dense wall of connective tissue to enter the lymph or blood streams even in the most chronic conditions.

The close proximity of the bacteria to the blood vessels and to active lesions has been noted in recently infected pulps; in granulomas which had existed for from five to twelve years, and in infected pulps of animals injected intravenously a short time previously. The sclerotic connective tissue should be regarded as the result of a long-continued infective process which tends to protect the surrounding

structures from bacterial invasion, but which has little power to prevent invasion of the blood or lymph streams. Indeed, by virtue of the density of the connective tissue, which allows no expansion, it might be regarded as tending to force the bacteria and their products during exacerbations of these infections along the line of least resistance into the circulation. It is not improbable that the plunger effect from mastication tends to drive the bacteria and their toxic products in apical infections in the same direction. Since pain in these areas is the result chiefly of pressure, the absence of this symptom should be regarded as evidence that free drainage, into the circulation, of the bacteria and their products is afforded, rather than as evidence of the harmlessness of these conditions. In the light of these findings, moreover, freedom from demonstrable systemic disease, often for long periods, in persons who harbor these infections may be considered to be due more to general resistance, to a natural or acquired immunity, than to a local protection from encapsulation of the microörganisms.

In order that an infection from septic foci may become established in remote body tissues, the same laws of resistance which affords protection against microbic invasion from other sources must be overcome. A focus of infection wherever found—it may be in the intestinal tract, which, for mechanical reasons, can neither heal nor drain —that is teeming with microörganisms, should be regarded as a test tube with permeable walls imbedded in the tissues where absorption channels for bacteria and their products are present. In consequence, the play between the living bacteria and their products, and the protective mechanism of the host, becomes forced. A certain degree of immunity no doubt results, but since the bacteria (streptococci) usually present are poor antigens, the immunity induced is transient; and, since a state of increased susceptibility or hypersensitiveness from overstimulation may supervene, the protection may be inadequate. This is what occurs commonly during the immunization of horses and other animals with living streptococci, if the dose is not accurately gauged.

There is another reason why the mechanism of immunity may be inadequate to afford protection. By virtue of the gradation of oxygen pressure, and the presence of mixtures of bacteria in primary foci, the

bacteria may change in immunologic characteristics and in infecting powers. In that case the antibodies previously formed would be valueless. Before antibodies which would react with the new strains could be formed, opportunity for invasion and the production of localized lesions by the changed organisms could occur.

It has been stated by some workers that the bacteria, especially streptococci, from chronic localized dental infections are avirulent, and therefore not to be considered of etiologic importance. If virulence is understood to mean the power of aerobic cultures of these organisms to kill animals by overwhelming infection following their injection, disregarding the fact that most of the diseases apparently due to focal infection remain localized and are not overwhelming infections, then this contention is correct; but, if virulence is taken to mean the power to produce lesions, as determined by careful necropsies in anesthetized animals, it does not hold. By the use of cultures grown under partial oxygen tension, we have found that the bacteria in many of these foci are pathogenic, in some instances markedly so, and that they tend to lodge and produce lesions in the tissues or organs of animals, corresponding to those involved in the patient from whom the culture is taken. This finding is in accord with the rather common occurrence of acute exacerbations in these infections following various manipulations through the root canals in attempts at sterilization. The results with partial-oxygen-tension cultures lend some support to the view held by many that this phenomenon is associated in some way with the entrance of air or oxygen.

The importance of affording the bacteria in these experiments a gradient of oxygen pressure, and of injecting the bacteria soon after isolation, cannot be too strongly emphasized. The first consideration, in this study, has been to determine whether the foci contain living bacteria which can reproduce the disease in animals. If aerobic cultures only are made, no growth may occur in inclosed foci in which partial or complete anaerobes are present; or, only nonpathogenic organisms may develop, as in open infections such as pyorrhea, in which a mixture is constantly present. Thus, negative results in animals injected with a pure culture, such as green-producing streptococci grown aerobically, have little value since it is quite likely that the parasitic strain failed to grow or that the property on which

localization depends has been destroyed. By the use of methods embodying these principles, specific and other lesions have been produced with bacteria from the various types of dental focal infections such as gingivitis, pyorrhea, infected pulps, apical abscesses, discharging sinuses, and granulomas.

The tendency to produce lesions in the pulps of teeth in animals was more marked when bacteria from infected pulps were used than when they were taken from other dental foci or foci elsewhere. This was especially true if the pulp showed evidence of recent infection. In some instances, however, lesions resulted from the use of strains isolated from tonsils or other foci outside the dental field. In one case of recurring attacks of pyorrhea, injection of animals with cultures from the pus pockets, during an acute attack, caused hemorrhage and edema of peridental membranes. Parallel series of animals were injected with cultures from infected tonsils and various dental foci in many of the cases, and in some with cultures from the metastatic lesions as well. Usually the localizations were strikingly similar. The injection of the primary cultures of pus from tonsils and open infections about the teeth, such as pyorrhea, tended toward a wider range of localization than that which followed injection of cultures from enclosed infections about the teeth and about the metastatic lesions. Lesions in the tonsils of animals were found in only a few instances, and only when the lymphoid tissue in other parts of the body was hemorrhagic. This finding is to be expected since the tonsils studied showed little evidence of inflammation, and since the infection in the pockets in these organs is really outside the tonsil proper. The injection of a single small dose was sufficient at times to produce the specific localization, but a fair sized dose should be injected before the result is considered negative.

In order to simulate the condition in the patient more closely, in that the bacteria would need to pass through a series of capillaries before reaching the specific tissue, in some of the diseases studied, intraperitoneal injections were made with cultures. Even this method was followed by elective localizations in some instances. In the experiments with pus from tonsils, a small number of the bacteria which had grown in the focus was sufficient for elective localization. In parallel experiments, which will be reported shortly in a study on

myositis, cultures of pus from tonsils from normal persons and from persons suffering from metastatic disease show that the former may be harmless, and that the latter are prone to produce lesions in the tissues corresponding to those involved in the patient.

The identity of streptococci isolated from specific experimental lesions, following injection of cultures from foci of infection and the metastatic lesion, has been established in some instances. Improvement occurred in patients from whom foci were removed, which were proved to contain the specific organism at the time of removal. The organisms have been demonstrated in the lesions in animals, although absent elsewhere, by cultures and in sections (20, 33, 34, 35). Reinjection in animals produces characteristic lesions, and the organisms may again be isolated. Experiments with filtrates of the cultures have proved the absence of a filtrable virus. The requirements for the demonstration of etiologic relationship between extraneous parasites to disease have been fulfilled.

The results reported heretofore on elective localization of bacteria from foci of infection have been verified and extended. The findings warrant the conclusion that chronic foci of infection about the teeth are potentially or actually detrimental to the health of the persons who harbor them. The lesions which are more or less enclosed, and which drain only into the circulation, are probably the most dangerous and should be regarded as veritable experiments, which alone or in connection with predisposing factors will sooner or later break down the resistance of the patient and produce disease. The harm from oral sepsis, according to the experiments with emulsions from the infected tonsils and with the bacteria in the pus from tonsils, may be due to absorption of poisonous bacterial products and to the living bacteria themselves. The places of localization of bacteria, aside from the influence of a lowered resistance, local or general, and from that of injury, fatigue, strain, improper food, bad hygiene, disease, heredity, etc., will depend largely on the peculiar infective capacity, or the peculiar poison-producing power, of the bacteria at hand.

Clinical findings

Let us consider the frequency of probably the most dangerous form of dental sepsis: pulpless teeth and blind abscesses. Howe (22) reports the presence of 40,000 abscessed teeth in an examination of 50,000 children at the Forsythe Dental Infirmary, and points out that abscessed teeth must be of little importance as a source of infection since arthritis deformans (a disease which rarely occurs in childhood) was not observed. It is to be regretted that no information is given with regard to the condition of these children at the time of the examination, for example; or to the number who later suffered from malnutrition, hypertrophied and infected tonsils and adenoids, leading to malformation of the jaw, to defective teeth, and to deficient mental and physical development; or to the number who had appendicitis, endocarditis and so-called "idiopathic" infections, fatal or otherwise, in which the teeth were not even suspected as being a possible source of these infections. Langstroth (25), in his studies of cases at the University of California Hospital, found chronic focal infections in 84 per cent of ulcer patients, in 66 per cent of subacute cases of arthritis, in 73 per cent of the chronic cases of arthritis, and in 100 per cent of the gall-bladder cases. The acute and subacute cases responded well after removal of the foci, even to the point of absolute cure. In many of the chronic cases, the patients had less pain and no further progression of the disease. Duke (10), in tabulating 1000 medical cases in which the patients suffered from some form of chronic disease, found a marked degree of oral sepsis in 66 per cent. Thoma (49) in a similar group of cases at the Robert B. Brigham Hospital in Boston found alveolar abscess in 88 per cent. Irons (23) found alveolar abscess in 44 per cent in a series of 124 patients with miscellaneous diseases. Abscesses were present in 76 per cent of the arthritis group and in 47 per cent of the nephritis group. Black (4) found that the peridental infections, without reference to complaint, were 56 per cent in persons under twenty-five years of age, 72 per cent in persons between twenty-five and thirty, 87 per cent in persons between thirty and forty, 89 per cent in persons between forty and fifty, and 100 per cent in persons more than fifty. Many of these infections are found in teeth from which the pulp has

been removed artificially and the canals improperly filled, as is shown by Ulrich (51), who found that 68 per cent of all artificially devitalized teeth had apical abscesses; and that, of 1350 so-called dead teeth examined, 83 per cent were abscessed. The number of persons suffering from diseases directly attributable to these infections, as well as from nonrelated conditions which have been cured or benefited by elimination of foci of infection in the various branches of medicine, is so large as to be quite sufficient to prove the general truth of the idea of causal relationship.

Therapeutic suggestions

The opportunity of the dental profession for coöperation with the various branches of medicine along these lines needs no emphasis. The prevention of oral sepsis in the future with a view to lessening the incidence of systemic disease should henceforth take precedence, in dental practice, over the preservation of the teeth almost wholly for mechanical or cosmetic purposes, as has been so largely the case in the past. Every effort should be made for the prevention of dental infections and for the correction of those already present. Preventive measures should begin in childhood with a view to obtaining perfect development of the teeth and oral cavity, and thus preventing various defects which would later lead to sepsis. This calls for the coöperation of dentist, pediatrist, and throat specialist.

The principles underlying various procedures for the prevention and cure of infections of the gums and enveloping membranes about the roots of teeth may be regarded as fairly well understood and effectively applied by many. It should be emphasized, however, that the chief harm from these conditions comes from the absorption of the bacteria and their products into the lymph stream or blood, especially if drainage is inadequate, not from swallowing the infectious material; and that the infections predispose to embolic infections within and without the dental field. The correction of pyorrhea and allied conditions is, therefore, of great importance.

Infections of the dental pulp, pulpless teeth, and apical abscesses are theoretically the most dangerous of the various forms of dental foci. They are usually free from symptoms and hence unsuspected.

They are situated in osseous tissue which allows no expansion. They lack drainage other than into the circulation and are exposed to pressure transmitted by the teeth during mastication. They remain active and do not heal for a period of years; and the bacteria, as shown in this study, are not encapsulated as is usually assumed, but are found in areas of active inflammatory reaction where new blood vessels form and afford ample drainage into the circulation.

On the basis of these facts, there can be no doubt that the wholesale devitalization of teeth, often for trivial reasons, and the filling of infected root canals without due regard to asepsis, as practiced in the past, result in the formation of numerous apical infections, and in much ill health. The instances of cure or improvement in systemic diseases directly attributable to these infections and in non-related conditions are so numerous, that the procedure as practiced heretofore should be regarded as a veritable experiment.

It is a well-known fact in bone surgery that no amount of antiseptic treatment will cure an osteomyelitis unless all dead tissue is removed and the dead spaces are eliminated; if this is done, healing occurs promptly without antiseptic treatment. In the filling of root canals the removal of every particle of pulp tissue is recognized as a prerequisite for successfully preventing subsequent infection. Is there any reason to believe that, if the small amount of dead albuminous matter in divergent or tortuous canals leads to reinfection (46), the larger amount in the apical region would not likewise become infected even though completely sterilized by ionization or other similar treatment? Hence it is doubtful whether any form of medication through the root canal, which would be applicable in routine practice, can be relied on successfully to sterilize the infected areas about abscessed teeth, and to prevent the areas from becoming reinfected. The fact that acute infections of the jaw occur not infrequently following these attempts is a further obstacle to the success of this method. Apicoectomy, while no doubt successful in removing the infection in the jaw in some instances, is applicable in only a small number of cases, and as a rule should not be attempted in persons who are ill from secondary systemic conditions. The removal of infected pulpless teeth, together with the infected peridental tissues therefore, seems to be the safest and surest means available at present for the cure of

these conditions. The many ingenious devices applicable to vital teeth will do much in making useful masticating surfaces and agreeable cosmetic effects.

It is becoming more and more apparent that the lack of improvement in systemic disease following the extraction of one or more infected teeth, barring other foci, may be due to the fact that the peridental infection was left or was only partially removed; also that the occurrence of acute exacerbations following extraction and curettement is commonly due to this cause. Persons who have had all their teeth extracted may still harbor localized areas of infection in the jaws. Simple extraction is not sufficient. The importance of eliminating dead spaces in curing infections of bone in other parts of the body—a lesson learned during the war—lends support to the idea of the "surgical removal" of infected teeth.

Removal would seem to be the method of choice in cases of extensive apical infections. If a person who is perfectly well has harbored for some years one or more devitalized teeth in which the x-ray findings are negative, there would seem to be no good reason for extraction. If, on the other hand, the person is suffering from arthritis, a heart or kidney affection, or some other form of disease for which other causes cannot be found, such teeth should be removed. Owing to the reparative power of the cementum, it would seem possible to devitalize teeth safely whose pulps are sterile and whose canals may be properly filled, provided the operation is done in an aseptic manner. This should be done after the removal of other sources of infection, and only in teeth of vital importance for restorative needs. The somewhat lowered resistance to infection of the peridental tissues about non-vital sterile teeth may be more than counterbalanced by the removal of the pulp, since most infections of otherwise sound teeth no doubt occur through this organ. In case of beginning infection of the pulp from decay which has not yet extended into the periapical tissues, attempts at sterilization, and, if necessary, removal of the pulp and filling the canal may be justified in some instances, but not until cultures have proved that the tissues are free from living bacteria; and only if the responsibility is shared conjointly by patient and operator.

In the matter of eliminating foci of infection in the mouth and

throat, the infections about teeth should as a rule be corrected first (44). Tonsillectomy as now so commonly practised before the condition of the teeth has been corrected is illogical. The lymphatics of the mouth and jaws drain into the tonsils. Some infections of tonsils improve or even disappear following the extraction of infected teeth. The unnecessary sacrifice of vital teeth should be condemned. Barker (1) states:

"I do not think a tooth should be sacrificed unless indications are clear for its removal. I would urge you not to give widespread orders to extract teeth unless they are so diseased that they must come out. On the other hand, please do not try to save teeth that cannot be made aseptic, for there is real danger that they may injure the rest of the body."

A patient who is suffering from a serious disease of focal origin, after due consideration of other factors for or against extraction of infected teeth, should be given the benefit of the doubt even when the evidence is not conclusive that the responsible focus is contained therein. Extraction will do no harm although inconvenient at the time, while non-extraction may result seriously.

"Not too much should be expected from the removal of a focus, especially in chronic conditions, because a similar condition may be present in inaccessible foci and in others too small to be detected. Moreover, recovery may be made difficult by local tissue sensitivity or peculiar mechanical conditions, and living bacteria in a metastatic lesion may continue the process independently of the focal source (42)."

The administration in guarded dosage of a properly prepared vaccine from a focus, following its removal, may be an important aid in overcoming the metastatic condition. But this or other forms of specific therapy cannot take the place of the eradication of the focus. It need hardly be pointed out that the prevention and cure of dental and other foci of infection is only a part of the problem. The conception of the problem of focal infection must not be too mechanical, for, as has been emphasized previously (44), and again demonstrated experimentally in this study, the invasive power of the bacteria is extremely important. The elimination of visible foci would not eliminate all systemic infections, for as the invasive power of the

bacteria increases, the need for forced entrance, as occurs from a focus, becomes less marked and thus the bacteria may gain entrance through the unabraded mucous membranes, as in the acute infectious diseases. But even here, the broken continuity from localized infections predisposes to these diseases (43, 46). The importance of hygiene, of a properly balanced diet, and of the general health, and hence the coöperation between the various branches of medicine and surgery, including dentistry, needs hardly be emphasized.

A careful study of the clinical and experimental data now available seems to show conclusively that a sane and comprehensive effort toward he prevention and cure of septic foci in the dental and other areas will result in the alleviation of human suffering, in a better preservation of the tissues in old age, in a longer average duration of life, in increased mental and physical efficiency, in the prevention and cure of acute and chronic disease, and, through the laws of heredity, make for a sturdier race.

BIBLIOGRAPHY

(1) Barker, L. F. 1919 Oral sepsis and the digestive apparatus. *Southern Med. Jour.*, xi, p. 481–484.

(2) Billings, F. 1912 Chronic focal infections and their etiologic relations to arthritis and nephritis. *Arch. Int. Med.*, ix, p. 484–498.

(3) Billings, F. 1914 Focal infection: Its broader application in the etiology of general disease. *Jour. Am. Med. Assn.*, lxiii, p. 899–903.

(4) Black, A. D. 1915 Ocular diseases resulting from dental lesions. *Ophth. Rec.*, xxiv, p. 610–622.

(5) Brown, R. O. 1919 A study on the etiology of cholecystitis and its production by the injection of streptococci. *Arch. Int. Med.*, xxiii, p. 185–189.

(6) Curtis, A. H. 1916 Streptococcus infection as a cause of spontaneous abortion. *Jour. Am. Med. Assn.*, lxvii, p.1739–1741.

(7) Davis, D. J. 1912 Bacteriological and experimental observations on focal infection. *Arch. Int. Med.*, ix, p. 505–514.

(8) Davis, W. T. 1915 The interrelation of the teeth and the eye. *Dental Cosmos*, lvii, p. 769–774.

(9) Dick, G. F., and Burmeister, W. H. 1913 The toxicity of human tonsils. *Jour. Inf. Dis.*, xiii, p. 273–279.

(10) Duke, W. W. 1918 Oral sepsis in its relation to systemic disease. St. Louis, C. V. Mosby Company, 124 pp.

(11) Gay, F. P. 1918 Recent aspects of streptococcus infection. *Jour. of Lab. and Clin. Med.*, iii, p. 721–757.

(12) Gilmer, T. L. 1912 Chronic oral infections. *Arch. Int. Med.*, ix, p. 499–504.

(13) Gilmer, T. L., and Moody, A. M. 1914 A study of the bacteriology of alveolar abscess and infected root canals. *Jour. Am. Med. Assn.*, lxiii, p. 2023–2024.

(14) GRÄF, H., AND WITTNEBEN, W. 1907 Zwei durch anäerobes Wachstum ausgezeichnete Streptokokken. *Centralbl. f. Bakteriol.*, xliv, p. 97–110.

(15) HARDT, L. L. J. 1916 Contributions to the physiology of the stomach. XXXIII —The secretion of gastric juice in cases of gastric and duodenal ulcer. *Am. Jour. Physiol.*, xl, p. 314–331.

(16) HARTZELL, T. B. 1916 The mouth as a factor in the pathogenesis of heart, kidney, and joint inflammations. *Jour.-Lancet*, xxxvi, p. 215–229.

(17) HARTZELL, T. B. 1916 Some evidences of the importance of the dental path as a source of serious localized and general infections. *Jour. Nat. Dental Assn.*, iii, p. 172–185.

(18) HARTZELL, T. B., AND HENRICI, A. T. 1916 The dental path; its importance as an avenue to infection. *Surg., Gynec. and Obst.*, xxii, p. 18–27.

(19) HELMHOLZ, H. F. 1909 The relation of duodenal ulcers to atrophic conditions of infants. *Arch. Ped.*, xxvi, p. 661–673.

(20) HELMHOLZ, H. F., AND BEELER, C. 1917 Focal lesions produced in the rabbit by colon bacilli isolated from pyelocystitis cases. *Am. Jour. Dis. Child.* xiv, p. 5–24.

(21) HELMHOLZ, H. F., AND BEELER, C. 1917 Experimental pyelitis in the rabbit. *Jour. Am. Med. Assn.*, lxix, p. 898–901.

(22) HOWE, P. R. 1919 To what degree are oral pathological conditions responsible for systemic disease? *Dental Cosmos*, lxi, p. 33–40.

(23) IRONS, E. E. 1916 Dental infections and systemic disease; treatment and results. *Jour. Am. Med. Assn.*, lxvii, p. 851–853.

(24) IRONS, E. E., BROWN, E. V. L., AND NADLER, W. H. 1916 The localization of streptococci in the eye. A study of experimental iridocyclitis in rabbits. *Jour. Inf. Dis.*, xviii, p. 315–334.

(25) LANGSTROTH, L. 1918 The incidence of chronic focal infection in chronic diseases. *Am. Jour. Med. Sc.*, clv, p. 232–238.

(26) LONGCOPE, W. T. 1914 Experimental nephritis caused by repeated protein intoxication. *Proc. New York Path. Soc.*, xiii, p. 120–123.

(27) MAJOR, R. H. 1916–1917 The production of kidney lesions with staphylococcus aureus toxins. *Jour. Med. Research*, xxxv, p. 349–356.

(28) MILLER, W. D. 1889 Die Microorganismen der Mündhöhle. Die örtlichen und allgemeinen Erkrankungen, welche durch dieselben hervorgerufen werden. Leipzig, A. Thieme, 325 pp.

(29) MOODY, A. M. 1916 Lesions in rabbits produced by streptococci from chronic alveolar abscesses. *Jour. Infect. Dis.*, xix, p. 515–525.

(30) PIERREPONT, E. S. 1917 The influence of maternal oral sepsis on the foetus and marasmic children. *Lancet*, i, p. 837–840.

(31) RAVITCH, M. L., AND STEINBERG, S. A. 1918 Relationship of focal infection and certain dermatoses. Further observations. *Jour. Am. Med. Assn.*, lxxi, p. 1273–1278.

(32) RHEIN, M. L. 1917 The retention of devitalized teeth without danger of focal infection. *Jour. Am. Med. Assn.*, lxix, p. 974–976.

(33) ROSENOW, E. C. 1909 Immunological and experimental studies on pneumococcus and staphylococcus endocarditis ("chronic septic endocarditis"). *Jour. Infect. Dis.*, vi, p. 245–281.

(34) ROSENOW, E. C. 1912 Experimental infectious endocarditis. *Jour. Infect. Dis.*, xi, p. 210–224.

(35) ROSENOW, E. C. 1913 The etiology of articular and muscular rheumatism. *Jour. Am. Med. Assn.*, lx, p. 1223–1224.

(36) ROSENOW, E. C. 1914 The etiology of acute rheumatism, articular and muscular. *Jour. Infect. Dis.*, xiv, p. 61–80.

(37) ROSENOW, E. C. 1914 The newer bacteriology of various infections as determined by special methods. *Jour. Am. Med. Assn.*, lxiii, p. 903–907.

(38) ROSENOW, E. C. 1915 Iritis and other ocular lesions on intravenous injection of streptococci. *Jour. Infect. Dis.*, xvii, p. 403–408.

(39) ROSENOW, E. C. 1915 The etiology and experimental production of erythema nodosum. *Jour. Infect. Dis.*, xvi, p. 367–384.

(40) ROSENOW, E. C. 1915 Elective localization of streptococci. *Jour. Am. Med. Assn.*, lxv, p. 1687–1691.

(41) ROSENOW, E. C. 1916 Elective localization of the streptococcus from a case of pulpitis, dental neuritis, and myositis. *Jour. Immunol.*, i, p. 363–381; also *Internat. Jour. Orthodontia*, ii, p. 713–725.

(42) ROSENOW, E. C. 1917 The relation of dental infection to systemic disease. *Dental Cosmos*, lix, p. 485–491.

(43) ROSENOW, E. C., AND V. HESS, C. L. 1917 An epidemic of septic sore throat due to milk. *Jour. Am. Med. Assn.*, lxviii, p. 1305–1307.

(44) ROSENOW, E. C. 1918 The pathogenesis of focal infection. *Jour. Nat. Dental Assn.*, v, p. 113–124.

(45) ROSENOW, E. C., TOWNE, E. B., AND V. HESS, C. L. 1918 The elective localization of streptococci from epidemic poliomyelitis. *Jour. Infect. Dis.*, xxi, p. 313–344.

(46) ROSENOW, E. C., AND WHEELER, G. W. 1918 The etiology of epidemic poliomyelitis. *Jour. Infect. Dis.*, xxii, p. 281–312.

(47) DE SCHWEINITZ, G. E. 1915 Concerning focal infections in their relation to certain disorders of the uveal tract. *Ophth. Rec.*, xxiv, p. 601–610.

(48) TALBOT, J. E. 1919 A theory on the etiology of the toxaemia of pregnancy, with or without convulsions. *Surg., Gynec. and Obstet.*, xxviii, p. 165–174.

(49) THOMA, K. H. 1917 Diagnosis and treatment of alveolar abscesses caused by the diseases of the dental pulp based on pathological and radiographic study. *Dental Items of Interest*, xxxix, p. 516–527.

(50) THOMA, K. H. 1916 Oral abscesses. Boston, Ritter and Co., 229 pp.

(51) ULRICH, H. L. 1916 The blind dental abscess. *Boston Med. and Surg. Jour.*, clxxiv, p. 169. (Abstract.)

(52) WHERRY, W. B., AND OLIVER, W. W. 1917 Further observations of the adaptation of parasitic microörganisms to a lowered oxygen tension. *Jour. Infect. Dis.*, xx, p. 28–34.

PLATE 1

FIG. 1. Drawing illustrating the condition of the eye in a case of keratitis and iritis with dental sepis (case 3458).

FIG. 2. Iritis in rabbit 1699 following injection of a culture from the foul pulp in a case of keratitis and iritis (case 3458).

FIG. 3. Reverse side of the iris shown in figure 2.

FIG. 4. Normal iris of an albino rabbit.

1

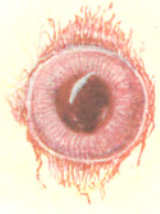

2



3

4

(Rosenow: Elective Localization of Bacteria)

PLATE 2

[*In the preparation of this plate the individual illustrations were reduced in size one-third ("one-third off"). The magnifications indicated below by the author, in the legends, refer to his original photographs.*]

FIG. 5. Photomicrograph of small granuloma near the apex of an extracted tooth whose root canal was improperly filled five years previously. Gram-Weigert, × 50. This specimen was obtained in a sterile manner, incubated at 35°C. for ten hours in the bottom of a tall tube of dextrose broth and then placed in 10 per cent formalin. The broth showed slight turbidity at the bottom due to streptococci. Note the dark area at *a*, near the apex of the granuloma; and the line at *b*, indicating the path of the blood vessels from this area.

FIG. 6. Photomicrograph revealing mass of streptococci in the dark area shown at *a*, in figure 5. Gram-Weigert, × 500. Painstaking search in serial sections showed this mass to be the only one throughout the tissue and hence it may be taken to indicate the point where the infection existed before the tooth was extracted.

FIG. 7. Granuloma at the apex of the left upper incisor of case 3458. Note the irregular large and small areas of cellular infiltration, and the embryonic and sclerotic connective tissue. Hematoxylin and eosin, × 50.

FIG. 8. Granuloma shown in figure 7. Gram-positive diplococci at *a*, in figure 7 Gram-Weigert, × 1000.

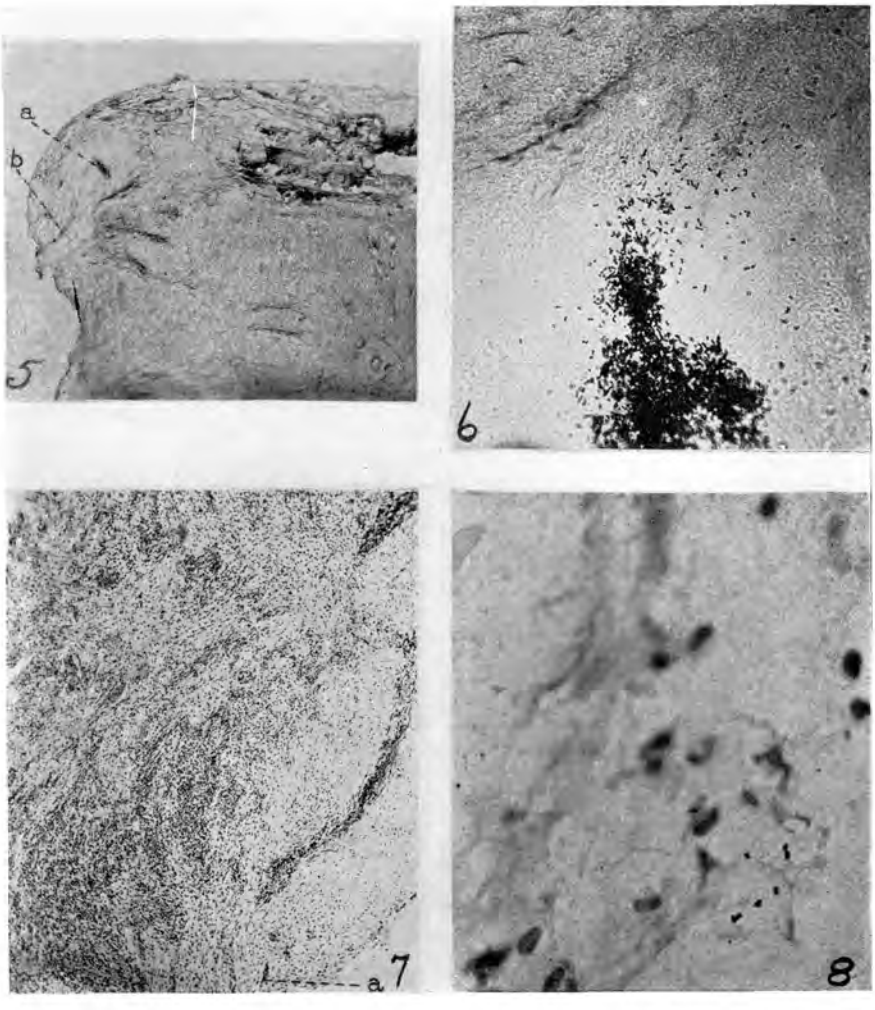

(Rosenow: Elective Localization of Bacteria)

PLATE 3

[*In the preparation of this plate the individual illustrations were reduced in size one-third ("one-third off"). The magnifications indicated below by the author, in the legends, refer to his original photographs.*]

FIG. 9. Granuloma shown in figure 7 after incubation in dextrose-acacia broth for ten hours. Note the dark area at *a*, consisting of a capillary filled with diplococci. The capillaries are lined with a single layer of endothelium at *b* and *c*. Hematoxylin and eosin, × 200.

FIG. 10. Granuloma shown in figure 9. Note the large dark area at the left consisting of Gram-positive diplococci, and the scattered leukocytes containing diplococci. This area corresponds to the one showing newly formed capillaries at *b*, figure 9. Gram-Weigert, × 500.

FIG. 11. Granuloma shown in figure 9. Note the capillary adjacent to the hemorrhagic and edematous area, containing leukocytes and diplococci. Gram-Weigert, × 1000.

FIG. 12. Section of the pulp of the first right upper bicuspid of case 3368. Note the area of round cell infiltration and the dark masses filling the blood vessels. Hematoxylin and eosin, × 120.

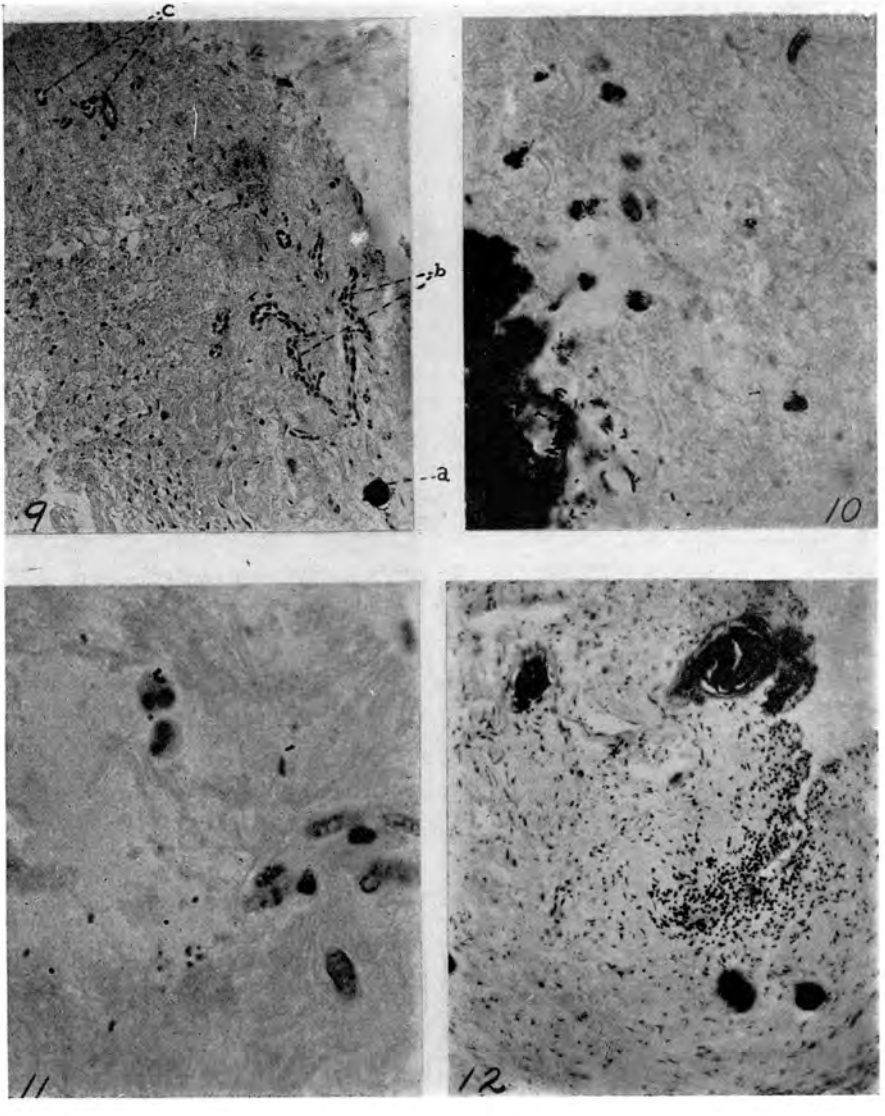

(Rosenow: Elective Localization of Bacteria)

PLATE 4

[*In the preparation of this plate the individual illustrations were reduced in size one-third ("one-third off"). The magnifications indicated below by the author, in the legends, refer to his original photographs.*]

FIG. 13. Higher magnification of the large blood vessel shown in figure 12. Note the large number of diplococci in the blood vessel, showing branching in the adjacent infiltrated tissue. Gram-Weigert, × 500.

FIG. 14. Section of the pulp of the left lower incisor of rabbit 1720 injected with the culture from the pulp of the tooth in case 3368. Note the areas of hemorrhage and leukocytic infiltration. Hematoxylin and eosin, × 200.

FIG. 15. Section of the dental pulp illustrated in figure 14 showing diplococci, leukocytes, and hemorrhage adjacent to the capillary. Gram-Weigert, × 1000.

FIG. 16. Section of the dental pulp shown in figure 14 after incubation for ten hours in dextrose-acacia broth. Note the large number of leukocytes in and adjacent to the capillaries. Hematoxylin and eosin, × 200.

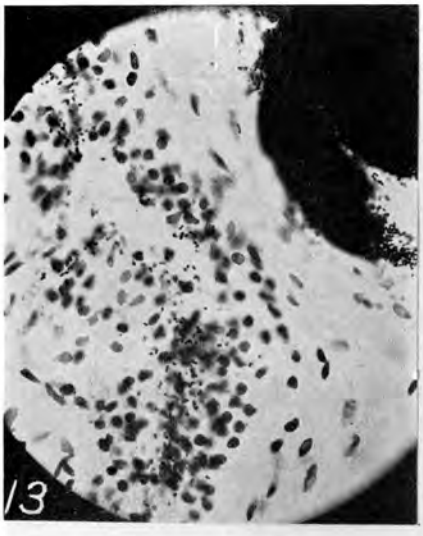

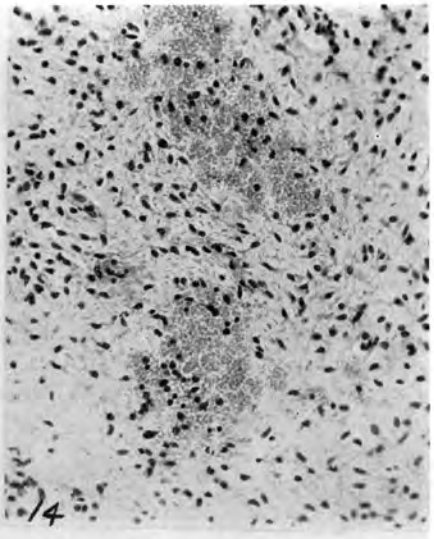

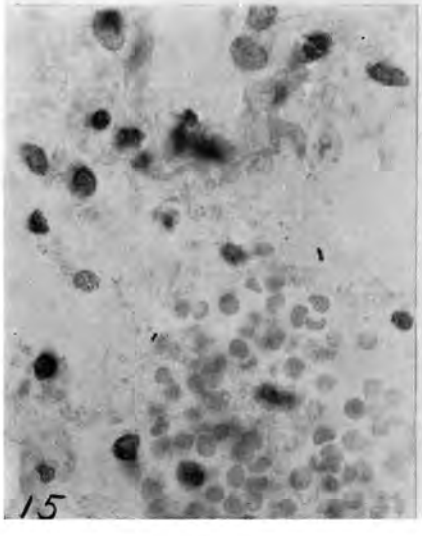

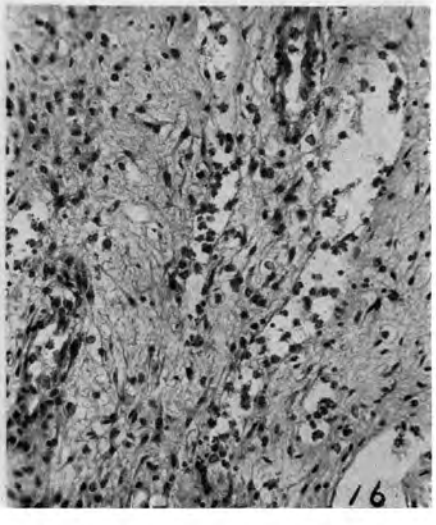

(Rosenow: Elective Localization of Bacteria)

PLATE 5

[*In the preparation of this plate the individual illustrations were reduced in size one-third ("one-third off"). The magnifications indicated below by the author, in the legends, refer to his original photographs.*]

FIG. 17. Dental pulp shown in figure 16. Note the large number of streptococci in and adjacent to the capillary walls, and in and along the lymph channels. Gram-Weigert, × 1000.

FIG. 18. Section of the ciliary body and iris of rabbit 1720, injected with the culture from the dental pulp of case 3368, showing marked hemorrhage and infiltration. Methylene blue and eosin, × 50.

FIG. 19. Section of the uvea of the eye of rabbit 1699, shown in figure 2, injected with a culture from the tooth in the case of keratitis and iritis. Note the marked hemorrhagic and leukocytic infiltration. Hematoxylin and eosin, × 100.

FIG. 20. *A*. Diplococcus in capillary of hemorrhagic ciliary body shown in figure 18. *B*. Diplococci in the hemorrhagic area shown in figure 19. Gram-Weigert, × 1000.

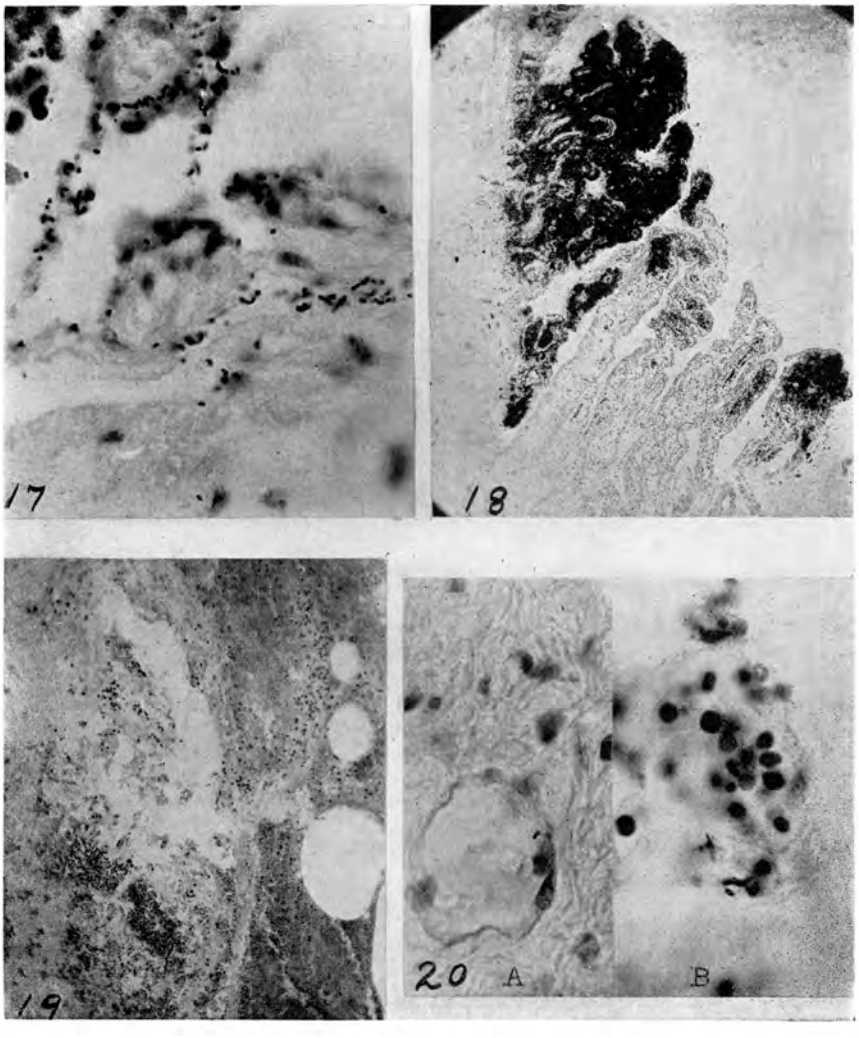

(Rosenow: Elective Localization of Bacteria)

PLATE 6

[*In the preparation of this plate the individual illustrations were reduced in size one-third ("one-third off"). The magnifications indicated below by the author, in the legends, refer to his original photographs.*]

FIG. 21. Nerve trunks of the lumbar plexus and sciatic nerve in rabbit 845 injected with a culture from the tooth in the case of lumbar neuritis (case 628). Note the hemorrhagic areas in the former and the absence of lesions in the latter. × 2.

FIG. 22. Posterior tibial and accompanying nerves and fascia of rabbit 1700 injected with cultures from the calcified pulp in case 3458. Note the extreme swelling and hemorrhage of the nerve and surrounding structures of the right leg including the bursa at the attachment of the tendon Achilles as compared with the same structures in the opposite side. × 1.

FIG. 23. Photograph of hemorrhagic dental pulps, left inferior dental nerve, posterior tibial nerves, and superficial muscles and aponeurosis of rabbit 1699 injected intravenously with a culture from the foul pulp of the left upper central incisor in case 3458.

FIG. 24. Hemorrhagic appendix of rabbit injected intravenously with the dextrose-brain-broth culture of streptococcus isolated from the tissues about the apex of a second left lower bicuspid devitalized twenty years previously. × $\frac{1}{2}$.

FIG. 25. Hemorrhagic and edematous area in the upper jaw of rabbit 1700.

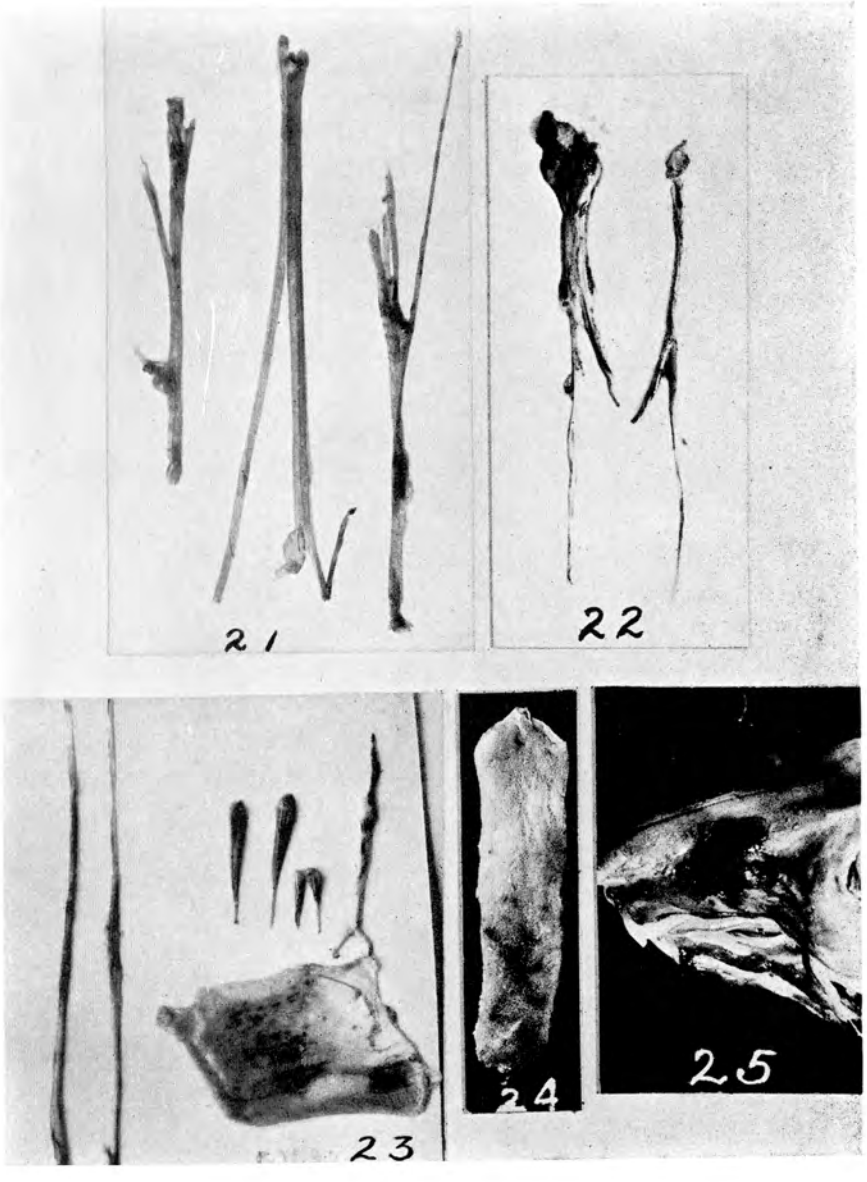

(Rosenow: Elective Localization of Bacteria)

PLATE 7

FIG. 26. Hemorrhagic area of intercostal muscles of rabbit 1700.
FIG. 27. Hemorrhagic area of intercostal muscles of fetus 4, rabbit 1700.

26

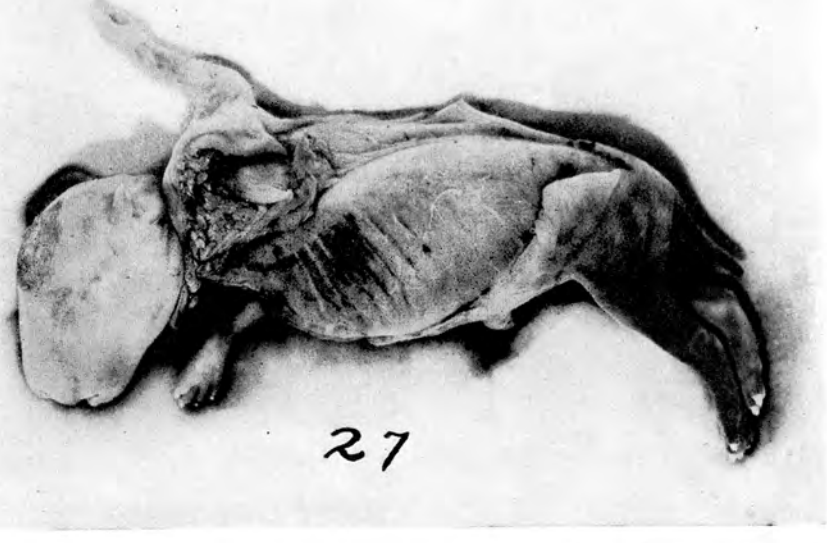

27

(Rosenow: Elective Localization of Bacteria

PLATE 8

[*In the preparation of this plate the individual illustrations were reduced in size one-third ("one-third off"). The magnifications indicated below by the author, in the legends, refer to his original photographs.*]

FIG. 28. Lesion in the gluteus maximus of rabbit 818 injected with a culture from a granuloma in a case of recurring attacks of gluteus myositis (case 623). Note the sharply circumscribed leukocytic infiltration and destruction of the muscle fibers. Hematoxylin and eosin, × 100.

FIG. 29. Section of gasserian ganglion in rabbit 908 injected with a culture from pus about teeth in a case of trigeminal neuralgia (case 674). Note the hemorrhage and leukocytic infiltration. Hematoxylin and eosin, × 100.

FIG. 30. Section of the left posterior tibial nerve of rabbit 746 injected intravenously with the culture from pyorrheal pockets in a case of multiple neuritis (case 595). Note the marked leukocytic infiltration and the separation of the nerve fibers. Hematoxylin and eosin, × 200.

FIG. 31. Section of anterior crural nerve of guinea-pig 156 injected intraperitoneally with a culture from a pyorrheal pocket in a case of multiple neuritis (case 595). Note the hemorrhage and leukocytic infiltration. Hematoxylin and eosin, × 120.

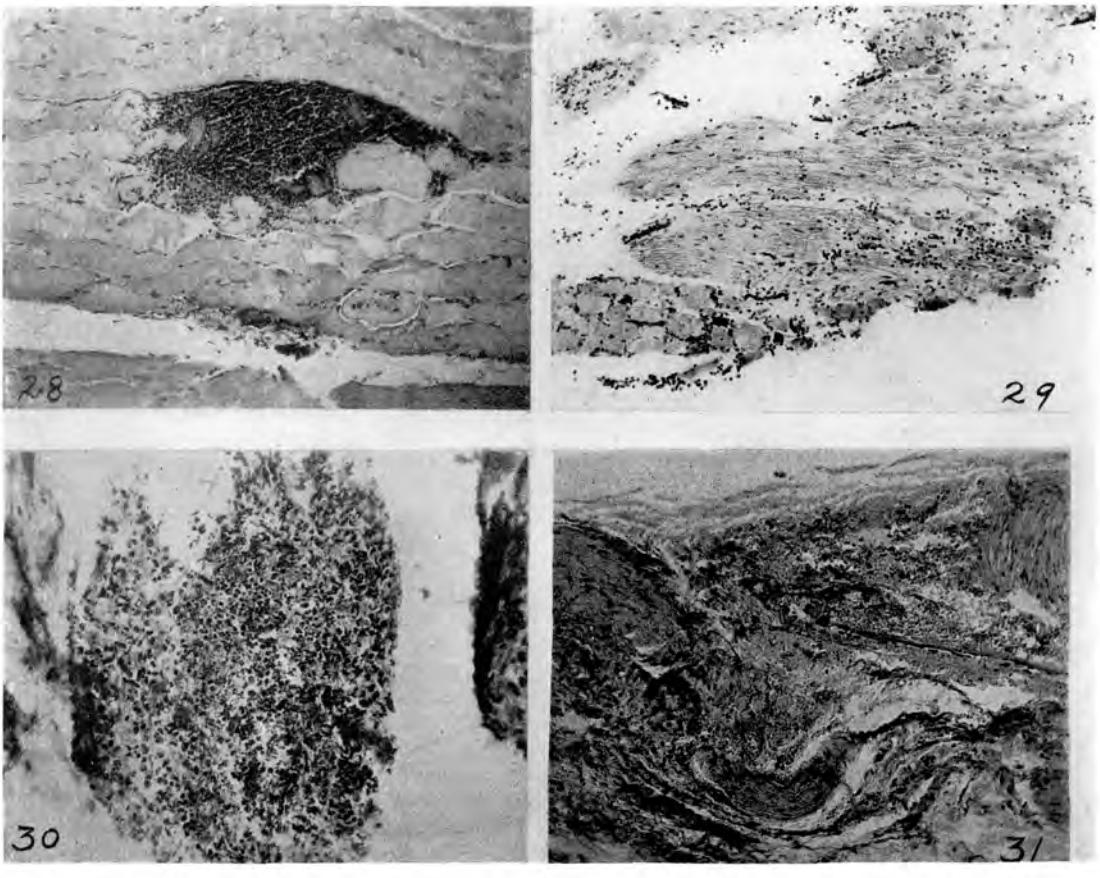

(Rosenow: Elective Localization of Bacteria)

PLATE 9

In the preparation of this plate the individual illustrations were reduced in size one-third ("one-third off"). The magnifications indicated below by the author, in the legends, refer to his original photographs.

FIG. 32. Section of the left internal popliteal nerve of guinea-pig 158 injected intravenously with a culture from pyorrheal pockets about teeth in a case of multiple neuritis after one animal passage. Note the edema, hemorrhage, and leukocytic infiltration between the nerve fibers. Hematoxylin and eosin, × 220.

FIG. 33. *A*. Section of hemorrhagic and edematous peridental membrane of a tooth of a guinea-pig injected intravenously with a culture of streptococcus from foul dental pulp in a case of pulpitis, dental neuritis, and myositis. Note the large number of diplococci. Gram-Weigert, × 1000.

B. Diplococci in the vagus ganglion in a rabbit injected intravenously with a culture of streptococcus from a case of pulpitis, dental neuritis, and myositis associated with marked vagotonic neurosis.

C. Diplococci in the hemorrhagic area of the sympathetic ganglion in the same rabbit (*B*).

D. Diplococci in the area of infiltration in the muscle shown in figure 28. Gram-Weigert, × 1000.

FIG. 34. *A*. Small diplococci in the hemorrhagic and edematous area of the gasserian ganglion shown in figure 24.

B. Small diplococci in the sensory root of the gasserian ganglion in the same animal (*A*). Gram-Weigert, × 1000.

FIG. 35. *A*. Diplococci and leukocytes in the right musculo-spiral nerve of rabbit 739 injected intravenously with a culture from pyorrheal pockets in a case of multiple neuritis (case 595).

B. Diplococci in the edematous area of the nerve shown in figure 32.

C. Diplococci in the area of infiltration shown in figure 30.

D and *E*. Chains of diplococci in the hemorrhagic and edematous areas in the nerve shown in figure 31. Gram-Weigert × 1000.

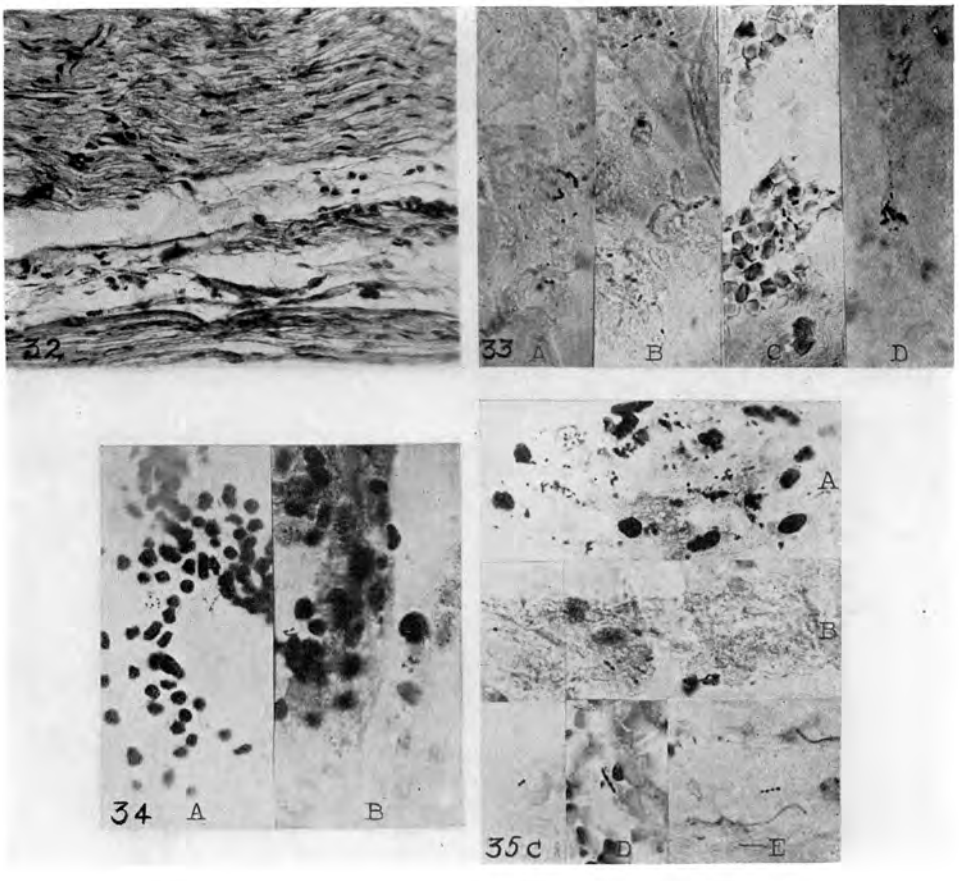

(Rosenow: Elective Localization of Bacteria)